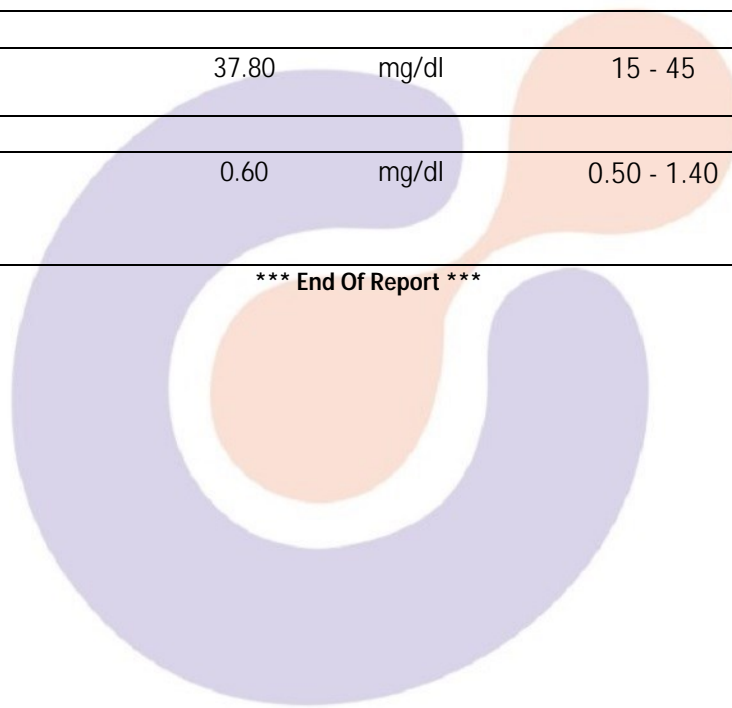


Patient Name : Mr. ISMAIL	Visit No : CHA250034162
Age/Gender : 40 Y/M	Registration ON : 25/Feb/2025 03:31PM
Lab No : 10131458	Sample Collected ON : 25/Feb/2025 03:33PM
Referred By : Dr. SAAOL HEART CENTRE	Sample Received ON : 25/Feb/2025 03:58PM
Refer Lab/Hosp : CHARAK NA	Report Generated ON : 25/Feb/2025 04:26PM
Doctor Advice : 2D ECHO,RANDOM,CREATININE,UREA	



Test Name	Result	Unit	Bio. Ref. Range	Method
BLOOD SUGAR RANDOM				
BLOOD SUGAR RANDOM	101	mg/dl	70 - 170	Hexokinase
BLOOD UREA				
BLOOD UREA	37.80	mg/dl	15 - 45	Urease, UV, Serum
SERUM CREATININE				
CREATININE	0.60	mg/dl	0.50 - 1.40	Alkaline picrate-kinetic

*** End Of Report ***



CHARAK



[Checked By]



Signature

Patient Name	: Mr. ISMAIL	Visit No	: CHA250034162
Age/Gender	: 40 Y/M	Registration ON	: 25/Feb/2025 03:31PM
Lab No	: 10131458	Sample Collected ON	: 25/Feb/2025 03:31PM
Referred By	: Dr.SAAOL HEART CENTRE	Sample Received ON	:
Refer Lab/Hosp	: CHARAK NA	Report Generated ON	: 25/Feb/2025 05:18PM

2D- ECHO & COLOR DOPPLER REPORT

1. **MITRAL VALVE STUDY** : MVOA - Normal (perimetry) cm² (PHT)

Anterior Mitral Leaflet:

- (a) **Motion**: Normal (b) **Thickness** : Normal (c) **DE** : 1.7 cm.
 (d) **EF** 123 mm/sec (e) **EPSS** : 06 mm (f) **Vegetation** : -
 (g) **Calcium** : -

Posterior mitral leaflet : Normal

- (a). **Motion** : Normal (b) **Calcium**: - (c) **Vegetation** : -

Valve Score : Mobility /4 Thickness /4 SVA /4
 Calcium /4 Total /16

2. **AORTIC VALVE STUDY**

- (a) **Aortic root** :3.4cms (b) **Aortic Opening** :2.0cms (c) **Closure**: Central
 (d) **Calcium** : - (e) **Eccentricity Index** : 1 (f) **Vegetation** : -

(g) **Valve Structure** : Tricuspid,

3. **PULMONARY VALVE STUDY** Normal

- (a) **EF Slope** : - (b) **A Wave** : + (c) **MSN** : -

(D) **Thickness** : (e) **Others** :

4. **TRICUSPID VALVE** : Normal

5. **SEPTAL AORTIC CONTINUITY** 6. **AORTIC MITRAL CONTINUITY**

Left Atrium : 3.1 cms **Clot** : - **Others** :
Right Atrium : Normal **Clot** : - **Others** : -

Contd.....



Patient Name	: Mr. ISMAIL	Visit No	: CHA250034162
Age/Gender	: 40 Y/M	Registration ON	: 25/Feb/2025 03:31PM
Lab No	: 10131458	Sample Collected ON	: 25/Feb/2025 03:31PM
Referred By	: Dr.SAAOL HEART CENTRE	Sample Received ON	:
Refer Lab/Hosp	: CHARAK NA	Report Generated ON	: 25/Feb/2025 05:18PM

VENTRICLES

RIGHT VENTRICLE : Normal

RVD (D)

RVOT

LEFT VENTRICLE :

LVIVS (D) 0.8 cm (s) 1.3 cm

Motion : normal

LVPW (D) 0.8cm (s) 1.4 cm

Motion : Normal

LVID (D) 4.7 cm (s) 2.9 cm

Ejection Fraction : **67%**

Fractional Shortening : **37 %**

TOMOGRAPHIC VIEWS

Parasternal Long axis view :

NORMAL LV RV DIMENSION
GOOD LV CONTRACTILITY.

Short axis view

Aortic valve level :

AOV - NORMAL
PV - NORMAL
TV - NORMAL

Mitral valve level :

MV - NORMAL

Papillary Muscle Level :

NO RWMA

Apical 4 chamber View :

No LV CLOT



Patient Name	: Mr. ISMAIL	Visit No	: CHA250034162
Age/Gender	: 40 Y/M	Registration ON	: 25/Feb/2025 03:31PM
Lab No	: 10131458	Sample Collected ON	: 25/Feb/2025 03:31PM
Referred By	: Dr.SAAOL HEART CENTRE	Sample Received ON	:
Refer Lab/Hosp	: CHARAK NA	Report Generated ON	: 25/Feb/2025 05:18PM

PERICARDIUM

Normal

DOPPLER STUDIES

	Velocity (m/sec)	Flow pattern (/4)	Regurgitation	Gradient (mm Hg)	Valve area (cm 2)
MITRAL	e = 0.7 a = 0.5	Normal	-	-	-
AORTIC	1.1	Normal	-	-	-
TRICUSPID	0.4	Normal	-	-	-
PULMONARY	1.0	Normal	-	-	-

OTHER HAEMODYNAMIC DATA

COLOUR DOPPLER

NO REGURGITATION OR TURBULENCE ACROSS ANY VALVE

CONCLUSIONS :

- NORMAL LV RV DIMENSION
- GOOD LV SYSTOLIC FUNCTION
- LVEF = 67 %
- NO RWMA
- ALL VALVES NORMAL
- NO CLOT / VEGETATION
- NO PERICARDIAL EFFUSION

OPINION – NORMAL 2D-ECHO & COLOUR DOPPLER STUDY

DR. RAJIV RASTOGI, MD,DM

*** End Of Report ***

