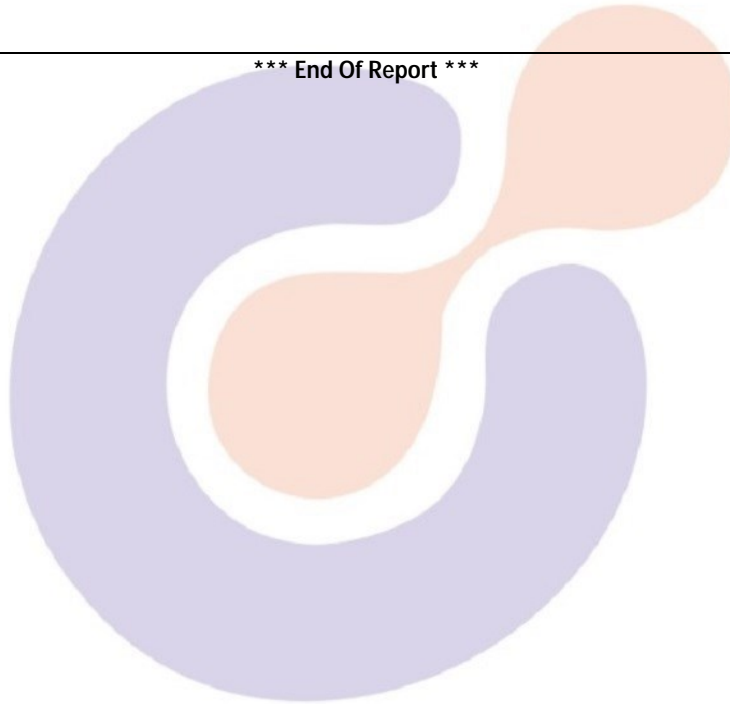


Patient Name : Mr.FAHAD KHAN Visit No : CHA250034556
Age/Gender : 18 Y/M Registration ON : 26/Feb/2025 10:03AM
Lab No : 10131852 Sample Collected ON : 26/Feb/2025 10:04AM
Referred By : Dr.RK MAURYA Sample Received ON : 26/Feb/2025 10:26AM
Refer Lab/Hosp : CHARAK NA Report Generated ON : 26/Feb/2025 11:41AM
Doctor Advice : CREATININE,USG WHOLE ABDOMEN



Test Name	Result	Unit	Bio. Ref. Range	Method
SERUM CREATININE				
CREATININE	0.90	mg/dl	0.50 - 1.40	Alkaline picrate-kinetic

*** End Of Report ***



CHARAK



[Checked By]



Sharma

DR. NISHANT SHARMA DR. SHADAB Dr. SYED SAIF AHMAD
PATHOLOGIST PATHOLOGIST MD (MICROBIOLOGY)

Patient Name	: Mr.FAHAD KHAN	Visit No	: CHA250034556
Age/Gender	: 18 Y/M	Registration ON	: 26/Feb/2025 10:03AM
Lab No	: 10131852	Sample Collected ON	: 26/Feb/2025 10:03AM
Referred By	: Dr.RK MAURYA	Sample Received ON	:
Refer Lab/Hosp	: CHARAK NA	Report Generated ON	: 26/Feb/2025 12:53PM

ULTRASOUND STUDY OF WHOLE ABDOMEN

- **Liver** is **borderline enlarged in size (~155mm)** and shows homogenous echotexture of liver parenchyma. No intrahepatic biliary radicle dilatation is seen. No space occupying lesion is seen. Hepatic veins and IVC are seen normally.
- **Gall bladder** is *partially distended*.
- **CBD** is normal at porta. No obstructive lesion is seen.
- **Portal vein** Portal vein is normal at porta.
- **Pancreas:** *Head and body appear normal. Rest of the pancreas is obscured by bowel gases.*
- **Spleen** is normal in size and shows homogenous echotexture of parenchyma. No space occupying lesion is seen. **Splenunculus of size approx 9.1 x 8.0mm is seen near splenic hila.**
- No ascites is seen.
- **Both kidneys** are normal in size and position. No hydronephrosis is seen. No calculus or mass lesion is seen. Cortico-medullary differentiation is well maintained. Parenchymal thickness is normal. No scarring is seen. Right kidney measures 126 x 41 mm in size. Left kidney measures 105 x 48 mm in size.
- **Urinary bladder** is normal in contour with anechoic lumen. No calculus or mass lesion is seen. UB walls are not thickened.
- **Prostate** is normal in size, measures 36 x 28 x 27 mm with weight of 15gms and shows homogenous echotexture of parenchyma.

IMPRESSION:

- **BORDERLINE HEPATOMEGALY.**

Clinical correlation is necessary.

[DR. JAYENDRA KUMAR, MD]

Transcribed by Gausiya

*** End Of Report ***

