

Patient Name	: Mr.QURBAN ALI	Visit No	: CHA250034785
Age/Gender	: 62 Y/M	Registration ON	: 26/Feb/2025 01:18PM
Lab No	: 10132081	Sample Collected ON	: 26/Feb/2025 01:18PM
Referred By	: Dr.RAJIV RASTOGI	Sample Received ON	:
Refer Lab/Hosp	: CHARAK NA	Report Generated ON	: 26/Feb/2025 04:57PM

2D- ECHO & COLOR DOPPLER REPORT

1. MITRAL VALVE STUDY : MVOA - Normal (perimetry) cm2 (PHT)

Anterior Mitral Leaflet:

- (a) Motion: Normal (b) Thickness : Normal (c) DE : 1.2 cm.
(d) EF :110 mm/sec (e) EPSS : 06 mm (f) Vegetation : -
(g) Calcium : -

Posterior mitral leaflet : Normal

- (a). Motion : Normal (b) Calcium: - (c) Vegetation : -
Valve Score : Mobility /4 Thickness /4 SVA /4
Calcium /4 Total /16

2. AORTIC VALVE STUDY

- (a) Aortic root :3.4cms (b) Aortic Opening :2.0cms (c) Closure: Central
(d) Calcium : - (e) Eccentricity Index : 1 (f) Vegetation : -

(g) Valve Structure : Tricuspid,

3. PULMONARY VALVE STUDY

- (a) EF Slope : - (b) A Wave : + (c) MSN : -

- (D) Thickness : (e) Others :

4. TRICUSPID VALVE : Normal

5. SEPTAL AORTIC CONTINUITY 6. AORTIC MITRAL CONTINUITY

- Left Atrium : 3.6cms Clot : - Others :
Right Atrium : Normal Clot : - Others : -

Contd.....



Patient Name	: Mr.QURBAN ALI	Visit No	: CHA250034785
Age/Gender	: 62 Y/M	Registration ON	: 26/Feb/2025 01:18PM
Lab No	: 10132081	Sample Collected ON	: 26/Feb/2025 01:18PM
Referred By	: Dr.RAJIV RASTOGI	Sample Received ON	:
Refer Lab/Hosp	: CHARAK NA	Report Generated ON	: 26/Feb/2025 04:57PM

VENTRICLES

RIGHT VENTRICLE : Normal

RVD (D)
RVOT

LEFT VENTRICLE :

LVIVS (D) 1.2 cm (s) 1.8cm

Motion : normal

LVPW (D) 1.3cm (s) 1.5cm

Motion : Normal

LVID (D) 4.4 cm (s) 2.4 cm

Ejection Fraction : 76%

Fractional Shortening : 44 %

TOMOGRAPHIC VIEWS

Parasternal Long axis view :

CONCENTRIC LVH
GOOD LV CONTRACTILITY.

Short axis view

Aortic valve level :

AOV - NORMAL
PV - NORMAL
TV - NORMAL

Mitral valve level :

MV - NORMAL

Papillary Muscle Level :

NO RWMA

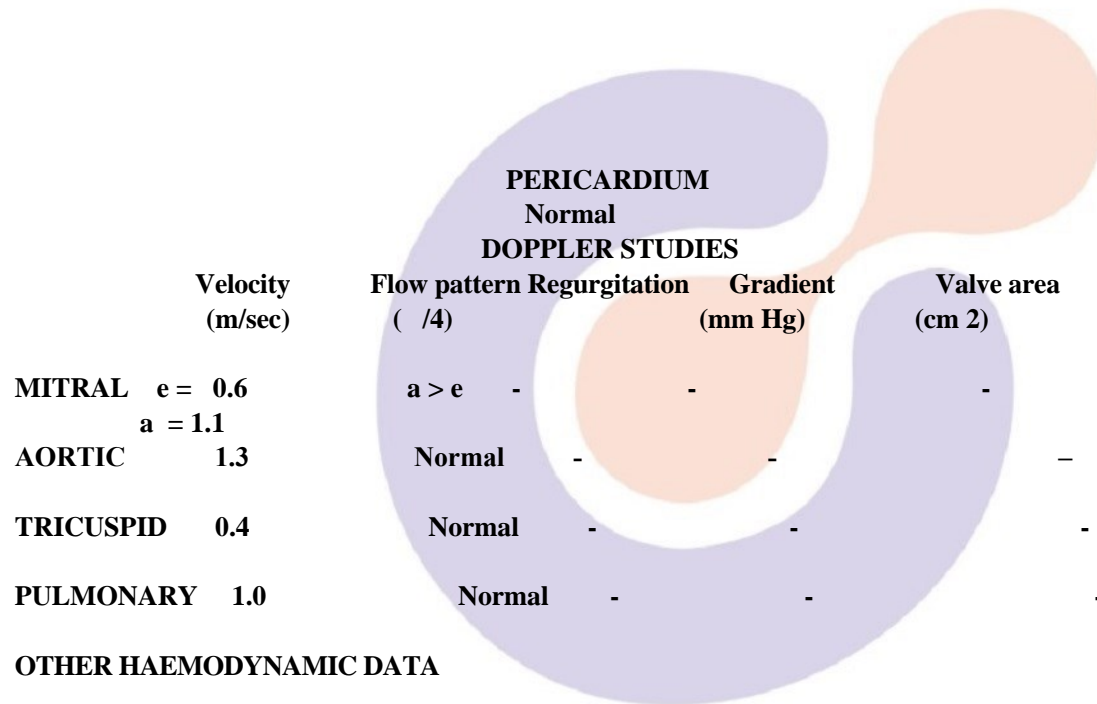
Apical 4 chamber View :

No LV CLOT



Patient Name	: Mr.QURBAN ALI	Visit No	: CHA250034785
Age/Gender	: 62 Y/M	Registration ON	: 26/Feb/2025 01:18PM
Lab No	: 10132081	Sample Collected ON	: 26/Feb/2025 01:18PM
Referred By	: Dr.RAJIV RASTOGI	Sample Received ON	:
Refer Lab/Hosp	: CHARAK NA	Report Generated ON	: 26/Feb/2025 04:57PM

Contd.



COLOUR DOPPLER

NO REGURGITATION OR TURBULENCE ACROSS ANY VALVE

CONCLUSIONS :

- CONCENTRIC LVH
- GOOD LV SYSTOLIC FUNCTION
- LVEF = 76%
- NO RWMA
- a > e
- NO CLOT / VEGETATION
- NO PERICARDIAL EFFUSION

OPINION-CONCENTRIC LVH

DR. RAJIV RASTOGI, MD,DM



Patient Name	: Mr.QURBAN ALI	Visit No	: CHA250034785
Age/Gender	: 62 Y/M	Registration ON	: 26/Feb/2025 01:18PM
Lab No	: 10132081	Sample Collected ON	: 26/Feb/2025 01:18PM
Referred By	: Dr.RAJIV RASTOGI	Sample Received ON	:
Refer Lab/Hosp	: CHARAK NA	Report Generated ON	: 26/Feb/2025 04:57PM

*** End Of Report ***

