

Patient Name	: Mr.AFSAR HASNAIN RIZVI	Visit No	: CHA250034888
Age/Gender	: 59 Y/M	Registration ON	: 26/Feb/2025 02:47PM
Lab No	: 10132184	Sample Collected ON	: 26/Feb/2025 02:47PM
Referred By	: Dr.RAJIV RASTOGI	Sample Received ON	:
Refer Lab/Hosp	: CHARAK NA	Report Generated ON	: 26/Feb/2025 03:58PM

2D- ECHO & COLOR DOPPLER REPORT

1. MITRAL VALVE STUDY : MVOA - Normal (perimetry) cm2 (PHT)

Anterior Mitral Leaflet:

- (a) Motion: Normal (b) Thickness : Normal (c) DE : 1.7 cm.
(d) EF : 65 mm/sec (e) EPSS : 06 mm (f) Vegetation : -
(g) Calcium : -

Posterior mitral leaflet : Normal

- (a). Motion : Normal (b) Calcium: - (c) Vegetation : -
Valve Score : Mobility /4 Thickness /4 SVA /4
Calcium /4 Total /16

2. AORTIC VALVE STUDY

- (a) Aortic root : 3.3cms (b) Aortic Opening : 1.7cms (c) Closure: Central
(d) Calcium : - (e) Eccentricity Index : 1 (f) Vegetation : -
(g) Valve Structure : Tricuspid, Normal

3. PULMONARY VALVE STUDY

- (a) EF Slope : - (b) A Wave : + (c) MSN : -
(D) Thickness : (e) Others :

4. TRICUSPID VALVE : Normal

5. SEPTAL AORTIC CONTINUITY 6. AORTIC MITRAL CONTINUITY

- Left Atrium : 2.9 cms Clot : - Others :
Right Atrium : Normal Clot : - Others : -

Contd.....



Patient Name	: Mr.AFSAR HASNAIN RIZVI	Visit No	: CHA250034888
Age/Gender	: 59 Y/M	Registration ON	: 26/Feb/2025 02:47PM
Lab No	: 10132184	Sample Collected ON	: 26/Feb/2025 02:47PM
Referred By	: Dr.RAJIV RASTOGI	Sample Received ON	:
Refer Lab/Hosp	: CHARAK NA	Report Generated ON	: 26/Feb/2025 03:58PM

VENTRICLES

RIGHT VENTRICLE : Normal

RVD (D)
RVOT

LEFT VENTRICLE :

LVIVS (D) 0.9 cm (s) 1.4cm

Motion : normal

LVPW (D) 0.8cm (s) 1.7cm

Motion : Normal

LVID (D) 5.1 cm (s) 3.2 cm

Ejection Fraction :67%

Fractional Shortening : 37%

TOMOGRAPHIC VIEWS

Parasternal Long axis view :

NORMAL LV RV DIMENSION
GOOD LV CONTRACTILITY.

Short axis view

Aortic valve level :

AOV - NORMAL
PV - NORMAL
TV - NORMAL

Mitral valve level :

MV - NORMAL

Papillary Muscle Level :

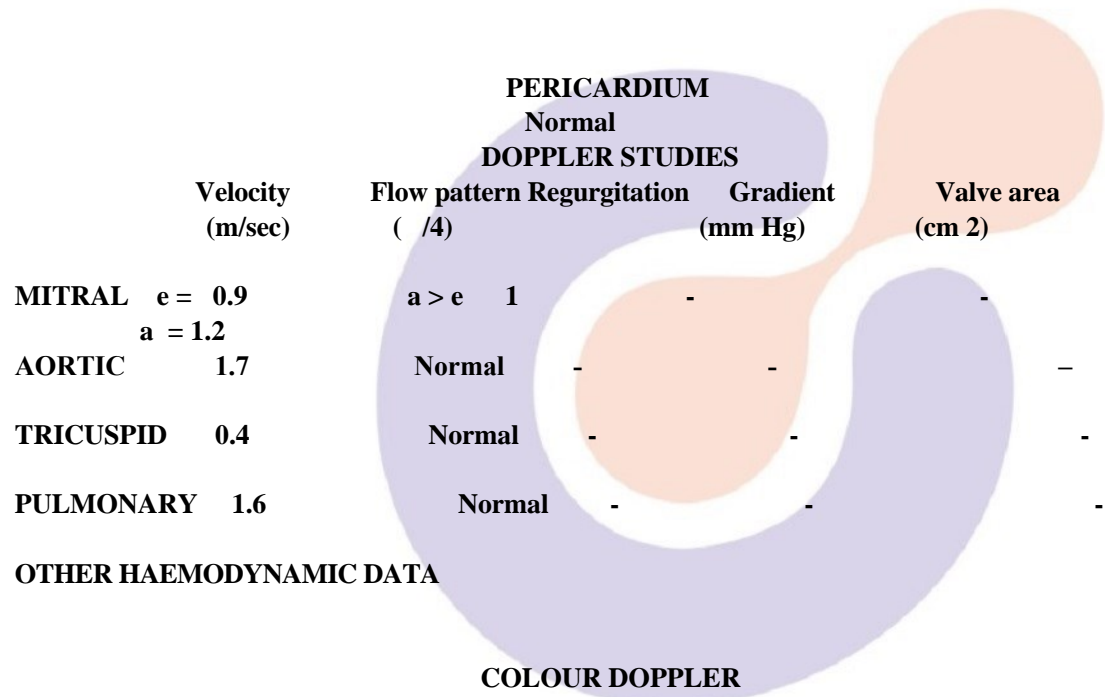
NO RWMA

Apical 4 chamber View :

No LV CLOT



Patient Name	: Mr.AFSAR HASNAIN RIZVI	Visit No	: CHA250034888
Age/Gender	: 59 Y/M	Registration ON	: 26/Feb/2025 02:47PM
Lab No	: 10132184	Sample Collected ON	: 26/Feb/2025 02:47PM
Referred By	: Dr.RAJIV RASTOGI	Sample Received ON	:
Refer Lab/Hosp	: CHARAK NA	Report Generated ON	: 26/Feb/2025 03:58PM



GR I / IV MR

CONCLUSIONS :

- NORMAL LV RV DIMENSION
- GOOD LV SYSTOLIC FUNCTION
- LVEF = 67 %
- NO RWMA
- MILD MR
- a > e
- NO CLOT / VEGETATION
- NO PERICARDIAL EFFUSION

DR. RAJIV RASTOGI, MD,DM

*** End Of Report ***



Patient Name : Mr.AFSAR HASNAIN RIZVI
Age/Gender : 59 Y/M
Lab No : 10132184
Referred By : Dr.RAJIV RASTOGI
Refer Lab/Hosp : CHARAK NA

Visit No : CHA250034888
Registration ON : 26/Feb/2025 02:47PM
Sample Collected ON : 26/Feb/2025 02:47PM
Sample Received ON :
Report Generated ON : 26/Feb/2025 03:58PM

