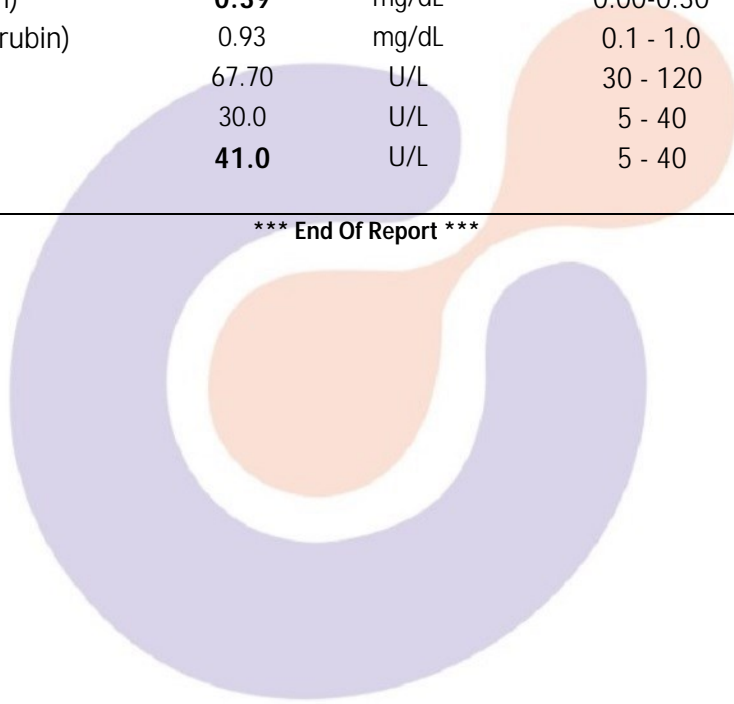


Patient Name : Mr.RASHID	Visit No : CHA250035321
Age/Gender : 48 Y/M	Registration ON : 27/Feb/2025 11:11AM
Lab No : 10132617	Sample Collected ON : 27/Feb/2025 11:13AM
Referred By : Dr.TULSI HOSPITAL	Sample Received ON : 27/Feb/2025 11:25AM
Refer Lab/Hosp : CHARAK NA	Report Generated ON : 27/Feb/2025 12:28PM
Doctor Advice : USG WHOLE ABDOMEN,LFT	



Test Name	Result	Unit	Bio. Ref. Range	Method
LIVER FUNCTION TEST				
TOTAL BILIRUBIN	1.32	mg/dl	0.4 - 1.1	Diazonium Ion
CONJUGATED (D. Bilirubin)	0.39	mg/dL	0.00-0.30	Diazotization
UNCONJUGATED (I.D. Bilirubin)	0.93	mg/dL	0.1 - 1.0	Calculated
ALK PHOS	67.70	U/L	30 - 120	PNPP, AMP Buffer
SGPT	30.0	U/L	5 - 40	UV without P5P
SGOT	41.0	U/L	5 - 40	UV without P5P

*** End Of Report ***



CHARAK



MC-2491

Print.Date/Time: 27-02-2025 13:05:18

*Patient Identity Has Not Been Verified. Not For Medicolegal



[Checked By]

DR. NISHANT SHARMA
PATHOLOGIST

DR. SHADAB
PATHOLOGIST

Dr. Aditi D Agarwal
DR. ADITI D AGARWAL
PATHOLOGIST

Patient Name : Mr.RASHID Visit No : CHA250035321
Age/Gender : 48 Y/M Registration ON : 27/Feb/2025 11:11AM
Lab No : 10132617 Sample Collected ON : 27/Feb/2025 11:11AM
Referred By : Dr.TULSI HOSPITAL Sample Received ON :
Refer Lab/Hosp : CHARAK NA Report Generated ON : 27/Feb/2025 12:33PM

ULTRASOUND STUDY OF WHOLE ABDOMEN

- **Liver** is mildly enlarged in size, and shows homogenously increased echotexture of liver parenchyma. No intrahepatic biliary radicle dilatation is seen. No space occupying lesion is seen. Hepatic veins and IVC are seen normally.
- **Gall bladder** is normal in size and shows a calculus measuring 25mm in lumen. No mass lesion is seen. GB walls are not thickened.
- **CBD** is normal at porta. No obstructive lesion is seen.
- **Portal vein** Portal vein is normal at porta.
- **Pancreas** is normal in size and shows homogenous echotexture of parenchyma. PD is not dilated. No parenchymal calcification is seen. No peripancreatic collection is seen.
- **Spleen** is normal in size and shows homogenous echotexture of parenchyma. No SOL is seen.
- No retroperitoneal adenopathy is seen.
- No ascites is seen.
- **Both kidneys** are normal in size and position. No hydronephrosis is seen. No calculus or mass lesion is seen. Cortico-medullary differentiation is well maintained. Parenchymal thickness is normal. No scarring is seen. Right kidney measures 102 x 45 mm in size. Left kidney measures 102 x 48 mm in size.
- **Ureters** Both ureters are not dilated. UVJ are seen normally.
- **Urinary bladder** is normal in contour with anechoic lumen. No calculus or mass lesion is seen. UB walls are not thickened.
- Bilateral seminal vesicles are seen normally.
- **Prostate** is borderline enlarged in size measures 33 x 38 x 35 mm with weight of 23 gms and shows homogenous echotexture of parenchyma. No mass lesion is seen.

OPINION:

- MILD HEPATOMEGALY WITH FATTY INFILTRATION OF LIVER GRADE-I.
- CHOLELITHIASIS
- BORDERLINE PROSTATOMEGALY

Clinical correlation is necessary.

[DR. R.K SINGH , MD]

*** End Of Report ***

