

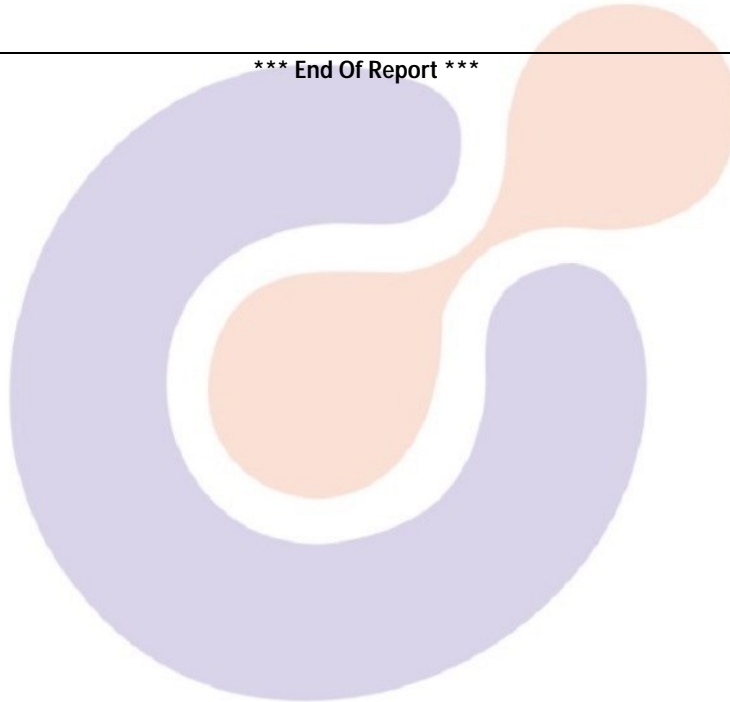
Patient Name : Ms.SADHAVI SAVITRI BAI FOOLE
Age/Gender : 44 Y/F
Lab No : 10133558
Referred By : Dr.ANUPAM SINHA **
Refer Lab/Hosp : CGHS (BILLING)
Doctor Advice : C SPINE AP /LAT,TPO

Visit No : CHA250036262
Registration ON : 28/Feb/2025 01:49PM
Sample Collected ON : 28/Feb/2025 02:04PM
Sample Received ON : 28/Feb/2025 02:41PM
Report Generated ON : 28/Feb/2025 04:25PM



Test Name	Result	Unit	Bio. Ref. Range	Method
Anti Thyroid Peroxidase Antibody(TPO)				
Anti Thyroid Peroxidase Antibody(TPO)	16.09	IU/ml	1 - 16	CLIA

*** End Of Report ***



CHARAK

[Checked By]

Print.Date/Time: 28-02-2025 17:04:49

*Patient Identity Has Not Been Verified. Not For Medicolegal



DR. NISHANT SHARMA
PATHOLOGIST

DR. SHADAB
PATHOLOGIST


DR. ADITI D AGARWAL
PATHOLOGIST

Patient Name : Ms.SADHAVI SAVITRI BAI FOOLE Visit No : CHA250036262
Age/Gender : 44 Y/F Registration ON : 28/Feb/2025 01:49PM
Lab No : 10133558 Sample Collected ON : 28/Feb/2025 01:49PM
Referred By : Dr.ANUPAM SINHA ** Sample Received ON :
Refer Lab/Hosp : CGHS (BILLING) Report Generated ON : 28/Feb/2025 02:51PM

SKIAGRAM CERVICAL SPINE AP AND LATERAL VIEW

- Anterior and posterior osteophytes are seen arising from C2-6 levels.
- Intervertebral disc space is reduced.
- Posterior elements are seen normally.
- No cervical rib is seen.
- No CVJ anomaly is seen.

OPINION:

- **CERVICAL SPONDYLOSIS WITH DEGENERATIVE DISC DISEASE.**

Adv: MRI cervical spine.

Clinical correlation is necessary.

[DR. RAJESH KUMAR SHARMA, MD]

Transcribed by R R...

*** End Of Report ***

