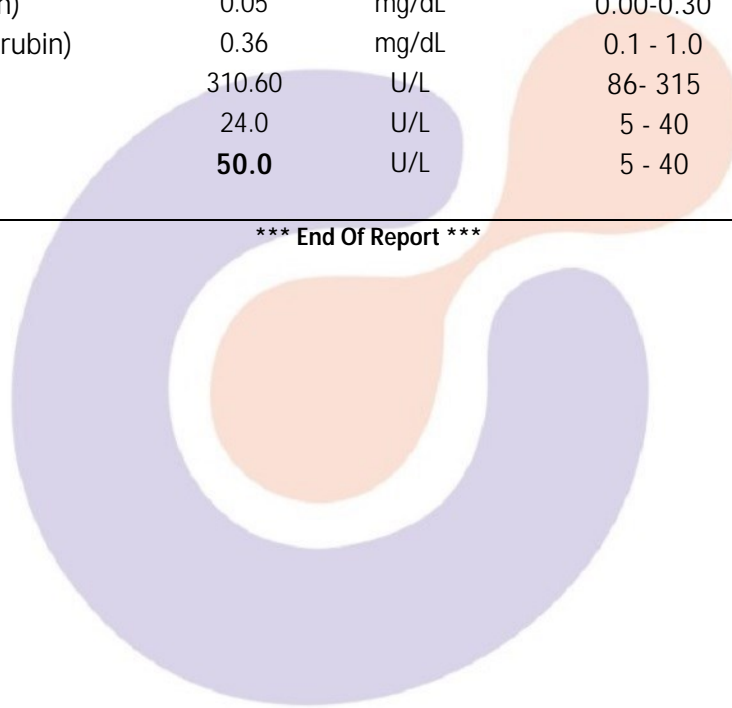


Patient Name : MasterRITIK	Visit No : CHA250036797
Age/Gender : 7 Y/M	Registration ON : 01/Mar/2025 10:28AM
Lab No : 10134093	Sample Collected ON : 01/Mar/2025 10:30AM
Referred By : Dr.YOGESH CHANDRA	Sample Received ON : 01/Mar/2025 10:32AM
Refer Lab/Hosp : CHARAK NA	Report Generated ON : 01/Mar/2025 12:34PM
Doctor Advice : USG WHOLE ABDOMEN,LFT	



Test Name	Result	Unit	Bio. Ref. Range	Method
LIVER FUNCTION TEST				
TOTAL BILIRUBIN	0.41	mg/dl	0.4 - 1.1	Diazonium Ion
CONJUGATED (D. Bilirubin)	0.05	mg/dL	0.00-0.30	Diazotization
UNCONJUGATED (I.D. Bilirubin)	0.36	mg/dL	0.1 - 1.0	Calculated
ALK PHOS	310.60	U/L	86- 315	PNPP, AMP Buffer
SGPT	24.0	U/L	5 - 40	UV without P5P
SGOT	50.0	U/L	5 - 40	UV without P5P

*** End Of Report ***



CHARAK



[Checked By]



DR. NISHANT SHARMA DR. SHADAB Dr. SYED SAIF AHMAD
PATHOLOGIST PATHOLOGIST MD (MICROBIOLOGY)

Patient Name	: MasterRITIK	Visit No	: CHA250036797
Age/Gender	: 7 Y/M	Registration ON	: 01/Mar/2025 10:28AM
Lab No	: 10134093	Sample Collected ON	: 01/Mar/2025 10:28AM
Referred By	: Dr.YOGESH CHANDRA	Sample Received ON	:
Refer Lab/Hosp	: CHARAK NA	Report Generated ON	: 01/Mar/2025 11:04AM

ULTRASOUND STUDY OF WHOLE ABDOMEN

- **Liver** is mildly enlarged in size and shows homogenous echotexture of liver parenchyma. No intrahepatic biliary radicle dilatation is seen. No space occupying lesion is seen. Hepatic veins and IVC are seen normally.
- **Gall bladder** is normal in size and shows anechoic lumen. No calculus / mass lesion is seen. GB walls are not thickened.
- **CBD** is normal at porta. No obstructive lesion is seen.
- **Portal vein** Portal vein is normal at porta.
- **Pancreas** is normal in size and shows homogenous echotexture of parenchyma. PD is not dilated. No parenchymal calcification is seen. No peripancreatic collection is seen.
- **Spleen** is normal in size and shows homogenous echotexture of parenchyma. No SOL is seen.
- Few prominent mesenteric lymphnodes are seen, size upto ~ 15 x 6.4 mm with maintained hilum.
- No ascites is seen.
- **Both kidneys** are normal in size and position. No hydronephrosis is seen. Tiny concretion measures ~ 1.2 mm is seen in mid pole of left kidney. No mass lesion is seen. Cortico-medullary differentiation is well maintained. Parenchymal thickness is normal. No scarring is seen. Right kidney measures 77 x 35 mm in size. Left kidney measures 75 x 35 mm in size.
- **Ureters** Both ureters are not dilated. UVJ are seen normally.
- **Urinary bladder** is normal in contour with multiple floating internal echoes in lumen. No calculus or mass lesion is seen. UB walls are not thickened.
- Pelvis organs are normal for child age group.

OPINION:

- **Mild hepatomegaly.**
- **Tiny left renal concretion.**
- **Multiple floating internal echoes in UB lumen -- cystitis.**
- **Few prominent mesenteric lymphnodes with maintained hilum.**

Clinical correlation is necessary.

[DR. R.K. SINGH, MD]



Patient Name	: MasterRITIK	Visit No	: CHA250036797
Age/Gender	: 7 Y/M	Registration ON	: 01/Mar/2025 10:28AM
Lab No	: 10134093	Sample Collected ON	: 01/Mar/2025 10:28AM
Referred By	: Dr.YOGESH CHANDRA	Sample Received ON	:
Refer Lab/Hosp	: CHARAK NA	Report Generated ON	: 01/Mar/2025 11:04AM

*** End Of Report ***

