

Patient Name	: Mr. IQBAL ALI	Visit No	: CHA250037202
Age/Gender	: 60 Y/M	Registration ON	: 01/Mar/2025 03:51PM
<b>Lab No</b>	<b>: 10134498</b>	Sample Collected ON	: 01/Mar/2025 03:51PM
Referred By	: Dr. JAN SWEA HOSPITAL	Sample Received ON	:
Refer Lab/Hosp	: CHARAK NA	Report Generated ON	: 01/Mar/2025 04:20PM

**2D- ECHO & COLOR DOPPLER REPORT**

1. MITRAL VALVE STUDY : MVOA - Normal (perimetry) cm2 (PHT)

**Anterior Mitral Leaflet:**

- (a) Motion: Normal (b) Thickness : Normal (c) DE : 1.7 cm.  
(d) EF : 80 mm/sec (e) EPSS : 06 mm (f) Vegetation : -  
(g) Calcium : -

**Posterior mitral leaflet : Normal**

- (a). Motion : Normal (b) Calcium: - (c) Vegetation : -  
Valve Score : Mobility /4 Thickness /4 SVA /4  
Calcium /4 Total /16

2. AORTIC VALVE STUDY

- (a) Aortic root : 3.1cms (b) Aortic Opening : 1.7cms (c) Closure: Central  
(d) Calcium : - (e) Eccentricity Index : 1 (f) Vegetation : -  
(g) Valve Structure : Tricuspid, Normal

3. PULMONARY VALVE STUDY

- (a) EF Slope : - (b) A Wave : + (c) MSN : -  
(D) Thickness : (e) Others :

4. TRICUSPID VALVE : Normal

5. SEPTAL AORTIC CONTINUITY 6. AORTIC MITRAL CONTINUITY

- Left Atrium : 2.1 cms Clot : - Others :  
Right Atrium : Normal Clot : - Others : -

Contd.....



Patient Name	: Mr. IQBAL ALI	Visit No	: CHA250037202
Age/Gender	: 60 Y/M	Registration ON	: 01/Mar/2025 03:51PM
<b>Lab No</b>	<b>: 10134498</b>	Sample Collected ON	: 01/Mar/2025 03:51PM
Referred By	: Dr. JAN SWEA HOSPITAL	Sample Received ON	:
Refer Lab/Hosp	: CHARAK NA	Report Generated ON	: 01/Mar/2025 04:20PM

VENTRICLES

**RIGHT VENTRICLE** : Normal

**RVD (D)**  
**RVOT**

**LEFT VENTRICLE** :

**LVIVS (D)** 0.9 cm (s) 1.2cm

**Motion** : normal

**LVPW (D)** 0.8cm (s) 1.4 cm

**Motion** : Normal

**LVID (D)** 4.2 cm (s) 2.6 cm

**Ejection Fraction** :67%

**Fractional Shortening** : 36 %

TOMOGRAPHIC VIEWS

**Parasternal Long axis view** :

NORMAL LV RV DIMENSION  
GOOD LV CONTRACTILITY.

**Short axis view**

**Aortic valve level** :

AOV - NORMAL  
**PV - NORMAL**  
TV - NORMAL

**Mitral valve level** :

MV - NORMAL

**Papillary Muscle Level** :

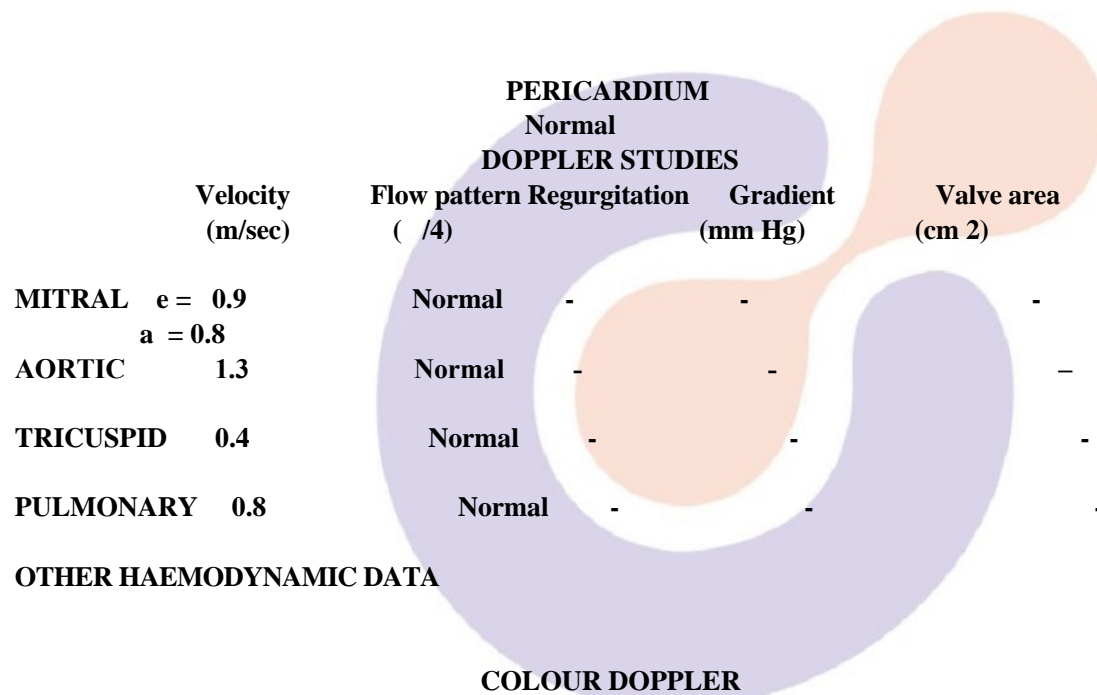
NO RWMA

**Apical 4 chamber View** :

No LV CLOT



Patient Name	: Mr. IQBAL ALI	Visit No	: CHA250037202
Age/Gender	: 60 Y/M	Registration ON	: 01/Mar/2025 03:51PM
<b>Lab No</b>	<b>: 10134498</b>	Sample Collected ON	: 01/Mar/2025 03:51PM
Referred By	: Dr. JAN SWEA HOSPITAL	Sample Received ON	:
Refer Lab/Hosp	: CHARAK NA	Report Generated ON	: 01/Mar/2025 04:20PM



NO REGURGITATION OR TURBULENCE ACROSS ANY VALVE

**CONCLUSIONS :**

- NORMAL LV RV DIMENSION
- GOOD LV SYSTOLIC FUNCTION
- LVEF = 67 %
- NO RWMA
- ALL VALVES NORMAL
- NO CLOT / VEGETATION
- NO PERICARDIAL EFFUSION

**OPINION – NORMAL 2D-ECHO & COLOUR DOPPLER STUDY**

**DR. RAJIV RASTOGI, MD,DM**



Patient Name	: Mr. IQBAL ALI	Visit No	: CHA250037202
Age/Gender	: 60 Y/M	Registration ON	: 01/Mar/2025 03:51PM
<b>Lab No</b>	<b>: 10134498</b>	Sample Collected ON	: 01/Mar/2025 03:51PM
Referred By	: Dr. JAN SWEA HOSPITAL	Sample Received ON	:
Refer Lab/Hosp	: CHARAK NA	Report Generated ON	: 01/Mar/2025 04:20PM

\*\*\* End Of Report \*\*\*

