

Patient Name	: Ms.SAREKHA	Visit No	: CHA250037691
Age/Gender	: 17 Y/F	Registration ON	: 02/Mar/2025 12:43PM
Lab No	: 10134986	Sample Collected ON	: 02/Mar/2025 12:43PM
Referred By	: Dr.SAIDAPUR N HOME	Sample Received ON	:
Refer Lab/Hosp	: CHARAK NA	Report Generated ON	: 02/Mar/2025 02:52PM

HIGH RESOLUTION ULTRASOUND STUDY OF RIGHT AXILLA
Study performed with 10.0MHz high frequency linear probe.

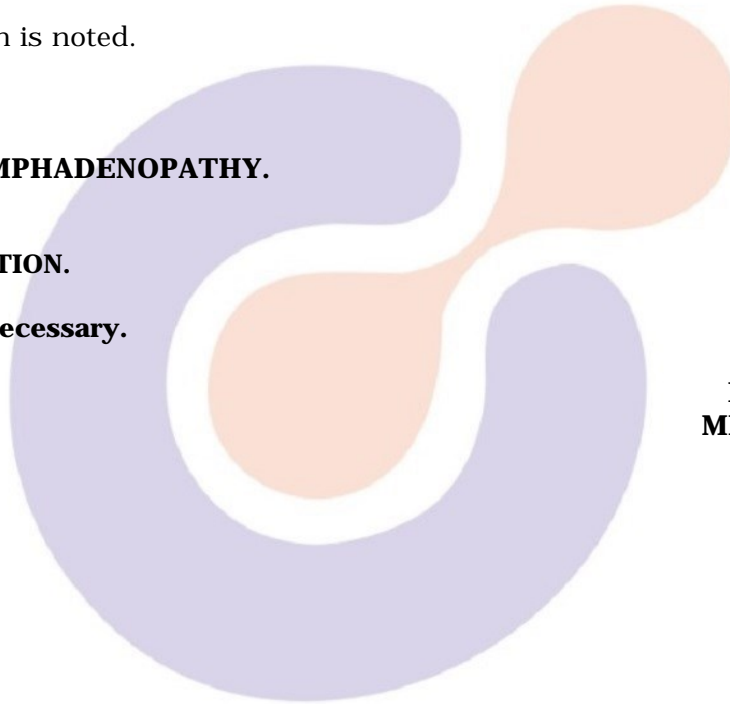
- **Multiple lymphnodes of variable sizes are noted in right axilla, largest of size 21 x 14 mm.**
- No evidence of collection is noted.

IMPRESSION:

- **RIGHT AXILLARY LYMPHADENOPATHY.**

ADV : FNAC CORRELATION.

Clinical correlation is necessary.



**DR. NISMA WAHEED
MD, RADIODIAGNOSIS**

(Transcribed by Rachna)

*** End Of Report ***

CHARAK

