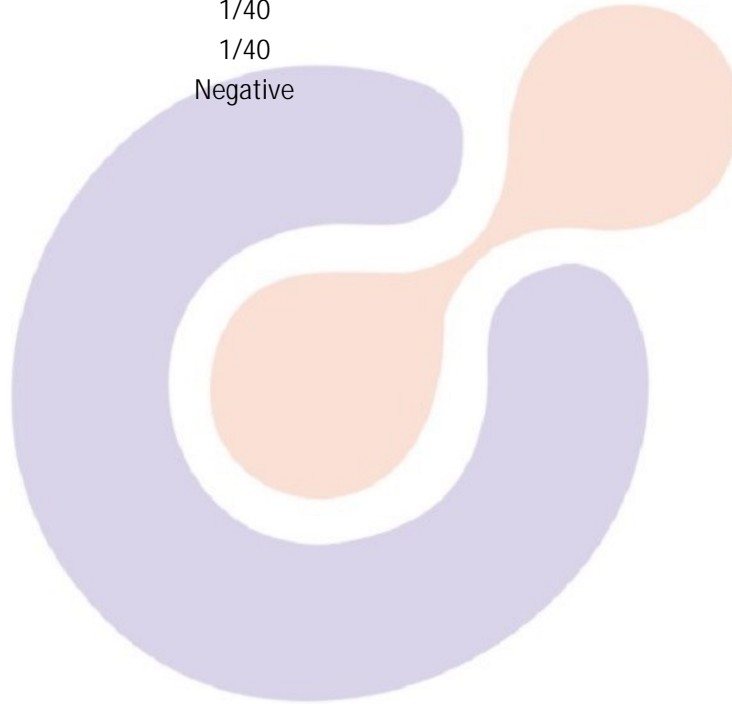


Patient Name : Mr.MOHD ZUBAIR	Visit No : CHA250038158
Age/Gender : 28 Y/M	Registration ON : 03/Mar/2025 12: 48PM
Lab No : 10135453	Sample Collected ON : 03/Mar/2025 12: 50PM
Referred By : Dr.ATUL CHAND RASTOGI	Sample Received ON : 03/Mar/2025 01: 03PM
Refer Lab/Hosp : CHARAK NA	Report Generated ON : 03/Mar/2025 02: 38PM
Doctor Advice : WIDAL,RANDOM,CHEST PA	



Test Name	Result	Unit	Bio. Ref. Range	Method
WIDAL				
Sample Type : SERUM				

SALMONELLA TYPHI O	1/40
SALMONELLA TYPHI H	1/40
NOTE:	Negative



CHARAK

[Checked By]

Print.Date/Time: 03-03-2025 15:10:40

*Patient Identity Has Not Been Verified. Not For Medicolegal



Sharma

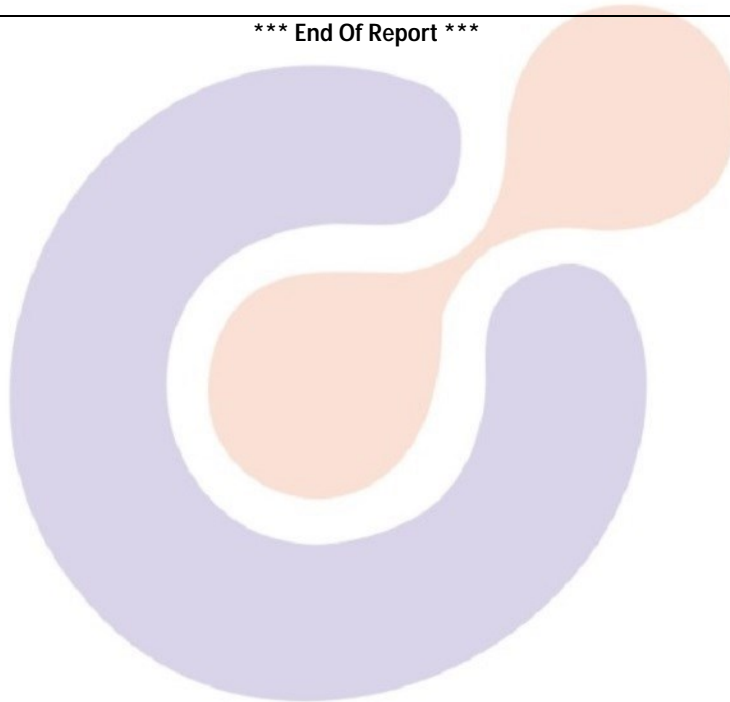
DR. NISHANT SHARMA DR. SHADAB Dr. SYED SAIF AHMAD
PATHOLOGIST PATHOLOGIST MD (MICROBIOLOGY)

Patient Name : Mr.MOHD ZUBAIR	Visit No : CHA250038158
Age/Gender : 28 Y/M	Registration ON : 03/Mar/2025 12: 48PM
Lab No : 10135453	Sample Collected ON : 03/Mar/2025 12: 50PM
Referred By : Dr.ATUL CHAND RASTOGI	Sample Received ON : 03/Mar/2025 01: 03PM
Refer Lab/Hosp : CHARAK NA	Report Generated ON : 03/Mar/2025 02: 21PM
Doctor Advice : WIDAL,RANDOM,CHEST PA	



Test Name	Result	Unit	Bio. Ref. Range	Method
BLOOD SUGAR RANDOM				
BLOOD SUGAR RANDOM	108.8	mg/dl	70 - 170	Hexokinase

*** End Of Report ***



CHARAK



[Checked By]



Sham

Patient Name	: Mr.MOHD ZUBAIR	Visit No	: CHA250038158
Age/Gender	: 28 Y/M	Registration ON	: 03/Mar/2025 12:48PM
Lab No	: 10135453	Sample Collected ON	: 03/Mar/2025 12:48PM
Referred By	: Dr.ATUL CHAND RASTOGI	Sample Received ON	:
Refer Lab/Hosp	: CHARAK NA	Report Generated ON	: 03/Mar/2025 02:15PM

SKIAGRAM CHEST PA VIEW

- Both lung fields are clear.
- Bilateral hilar shadows are prominent.
- Cardiac shadow is within normal limits.
- Both CP angles are clear.
- Soft tissue and bony cage are seen normally.
- Both domes of diaphragm are sharply defined.

IMPRESSION:

- NO ACTIVE LUNG PARENCHYMAL LESION IS DISCERNIBLE.

Clinical correlation is necessary.

[DR. RAJESH KUMAR SHARMA, MD]

TRANSCRIBED BY: ANUP

*** End Of Report ***

