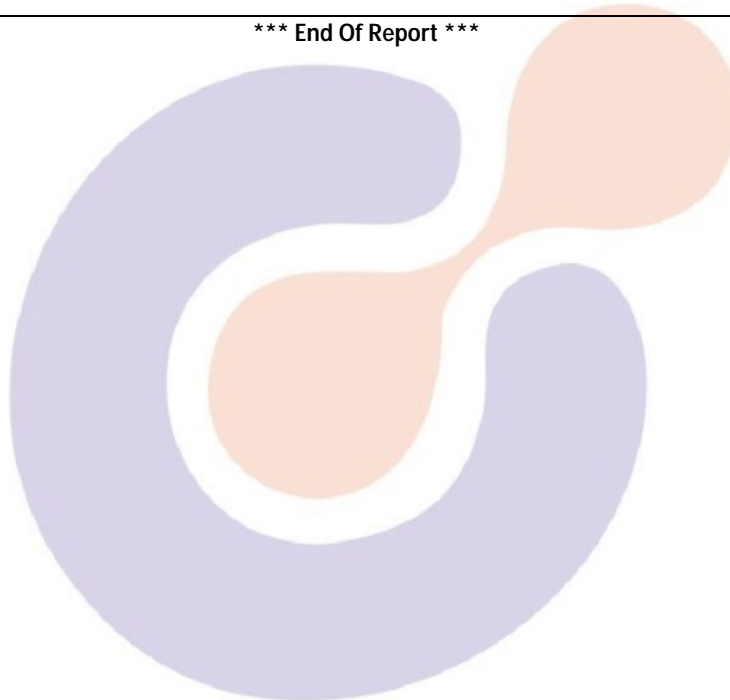


Patient Name : Mr.SHIV DIKSHIT
Age/Gender : 59 Y 5 M 27 D/M
Lab No : 10135918
Referred By : Dr.ROHAN BAJPAI
Refer Lab/Hosp : CGHS (DEBIT)
Doctor Advice : USG WHOLE ABDOMEN,AFP
Visit No : CHA250038623
Registration ON : 04/Mar/2025 08:04AM
Sample Collected ON : 04/Mar/2025 08:16AM
Sample Received ON : 04/Mar/2025 08:58AM
Report Generated ON : 04/Mar/2025 10:52AM



Test Name	Result	Unit	Bio. Ref. Range	Method
ALPHA-FETOPROTEIN (AFP)				
AFP	3.19	IU/ml	Upto 11.3	

*** End Of Report ***



CHARAK

[Checked By]

Print.Date/Time: 04-03-2025 11:25:07

*Patient Identity Has Not Been Verified. Not For Medicolegal



DR. NISHANT SHARMA DR. SHADAB Dr. SYED SAIF AHMAD
PATHOLOGIST PATHOLOGIST MD (MICROBIOLOGY)

Patient Name : Mr.SHIV DIKSHIT Visit No : CHA250038623
Age/Gender : 59 Y 5 M 27 D/M Registration ON : 04/Mar/2025 08:04AM
Lab No : 10135918 Sample Collected ON : 04/Mar/2025 08:04AM
Referred By : Dr.ROHAN BAJPAI Sample Received ON :
Refer Lab/Hosp : CGHS (DEBIT) Report Generated ON : 04/Mar/2025 08:58AM

ULTRASOUND STUDY OF WHOLE ABDOMEN

- **Liver** is mildly enlarged in size (~147mm) and shows mild coarsed echotexture of liver parenchyma. No intrahepatic biliary radicle dilatation is seen. No space occupying lesion is seen. Hepatic veins and IVC are seen normally.
- **Gall bladder** is normal in size and shows anechoic lumen. No calculus / mass lesion is seen. GB walls are not thickened.
- **CBD** is normal at porta. No obstructive lesion is seen.
- **Portal vein** Portal vein is normal at porta.
- **Pancreas** is normal in size and shows homogenous echotexture of parenchyma. PD is not dilated. No parenchymal calcification is seen. No peripancreatic collection is seen.
- **Spleen** is moderately enlarged in size (~165mm) and shows homogenous echotexture of parenchyma. No SOL is seen.
- No retroperitoneal adenopathy is seen.
- No ascites is seen.
- **Both kidneys** are normal in size and position. No hydronephrosis is seen. No calculus or mass lesion is seen. Cortico-medullary differentiation is well maintained. Parenchymal thickness is normal. No scarring is seen. Right kidney measures 94 x 37 mm in size. Left kidney measures 102 x 45 mm in size.
- **Ureters** Both ureters are not dilated. UVJ are seen normally.
- **Urinary bladder** is partially distended with anechoic lumen. No calculus or mass lesion is seen. UB walls are not thickened.
- Bilateral seminal vesicles are seen normally.
- **Prostate** is normal in size, measures 37 x 33 x 27 mm with weight of 17gms and shows homogenous echotexture of parenchyma. No mass lesion is seen.

OPINION:

- MILD HEPATOMEGALY WITH MILD COARSED ECHOTEXTURE OF LIVER PARENCHYMA WITH MODERATE SPLENOMEGALY - ? CHRONIC LIVER DISEASE (ADV: LFT & FIBRO SCAN).

Clinical correlation is necessary.

[DR. R. K. SINGH, MD]

Transcribed by Gausiya

*** End Of Report ***

