

Patient Name	: Mr.ABDUL HALEEM	Visit No	: CHA250038701
Age/Gender	: 60 Y/M	Registration ON	: 04/Mar/2025 09: 28AM
<b>Lab No</b>	<b>: 10135996</b>	Sample Collected ON	: 04/Mar/2025 09: 28AM
Referred By	: Dr.GALAXY HOSPITAL	Sample Received ON	:
Refer Lab/Hosp	: CHARAK NA	Report Generated ON	: 04/Mar/2025 11: 13AM

**2D- ECHO & COLOR DOPPLER REPORT**

1. **MITRAL VALVE STUDY** : MVOA - Normal (perimetry) cm2 (PHT)

**Anterior Mitral Leaflet:**

- (a) Motion: Normal (b) Thickness : Normal (c) DE : 1.7 cm.  
(d) EF : 76mm/sec (e) EPSS : 06 mm (f) Vegetation : -  
(g) Calcium : -

**Posterior mitral leaflet : Normal**

- (a). Motion : Normal (b) Calcium: - (c) Vegetation : -  
Valve Score : Mobility /4 Thickness /4 SVA /4  
Calcium /4 Total /16

2. **AORTIC VALVE STUDY**

- (a) Aortic root : 3.5cms (b) Aortic Opening : 2.1cms (c) Closure: Central  
(d) Calcium : - (e) Eccentricity Index : 1 (f) Vegetation : -

(g) Valve Structure : Tricuspid,

3. **PULMONARY VALVE STUDY**

- (a) EF Slope : - (b) A Wave : + (c) MSN : -

- (D) Thickness : (e) Others :

4. **TRICUSPID VALVE** : Normal

5. **SEPTAL AORTIC CONTINUITY** 6. **AORTIC MITRAL CONTINUITY**

- Left Atrium : 3.6 cms Clot : - Others :  
Right Atrium : Normal Clot : - Others : -

Contd.....



Patient Name	: Mr.ABDUL HALEEM	Visit No	: CHA250038701
Age/Gender	: 60 Y/M	Registration ON	: 04/Mar/2025 09: 28AM
<b>Lab No</b>	<b>: 10135996</b>	Sample Collected ON	: 04/Mar/2025 09: 28AM
Referred By	: Dr.GALAXY HOSPITAL	Sample Received ON	:
Refer Lab/Hosp	: CHARAK NA	Report Generated ON	: 04/Mar/2025 11: 13AM

VENTRICLES

**RIGHT VENTRICLE** : Normal

**RVD (D)**  
**RVOT**

**LEFT VENTRICLE** :

**LVIVS (D)** 1.0 cm (s) 1.4 cm

**Motion** : normal

**LVPW (D)** 1.0cm (s) 1.4 cm

**Motion** : Normal

**LVID (D)** 4.8 cm (s) 3.2 cm

**Ejection Fraction** :59%

**Fractional Shortening** : 31 %

TOMOGRAPHIC VIEWS

**Parasternal Long axis view** :

NORMAL LV RV DIMENSION  
GOOD LV CONTRACTILITY.

**Short axis view**

**Aortic valve level** :

AOV - NORMAL  
**PV - NORMAL**  
TV - NORMAL

**Mitral valve level** :

MV - NORMAL

**Papillary Muscle Level** :

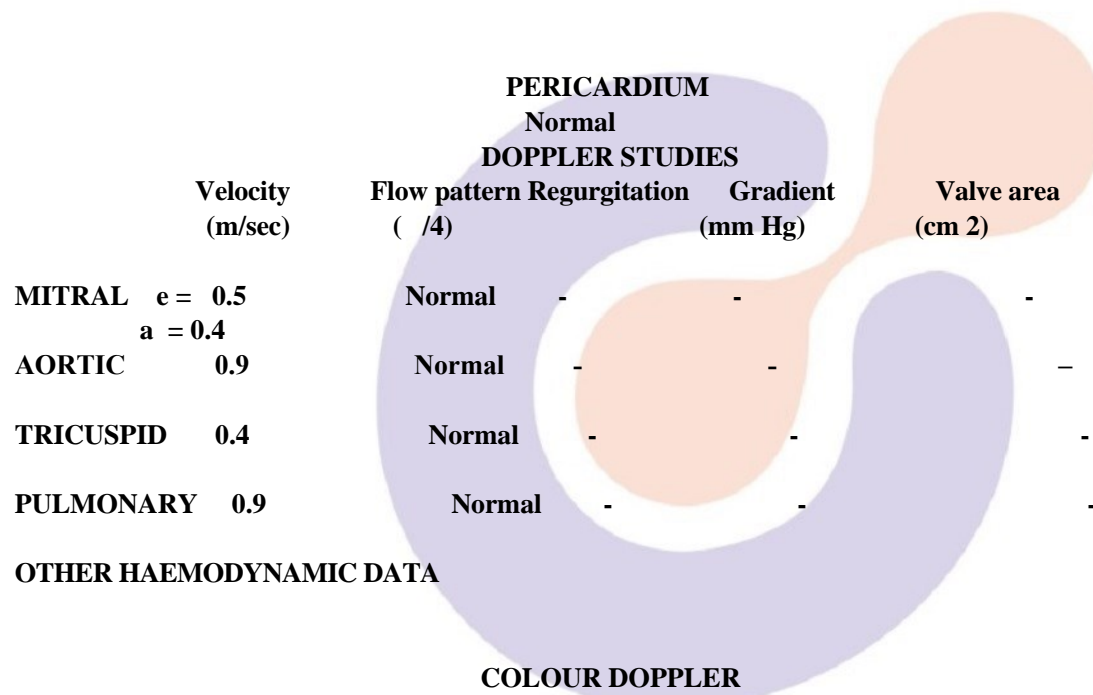
NO RWMA

**Apical 4 chamber View** :

No LV CLOT



Patient Name	: Mr.ABDUL HALEEM	Visit No	: CHA250038701
Age/Gender	: 60 Y/M	Registration ON	: 04/Mar/2025 09: 28AM
<b>Lab No</b>	<b>: 10135996</b>	Sample Collected ON	: 04/Mar/2025 09: 28AM
Referred By	: Dr.GALAXY HOSPITAL	Sample Received ON	:
Refer Lab/Hosp	: CHARAK NA	Report Generated ON	: 04/Mar/2025 11: 13AM



**NO REGURGITATION OR TURBULENCE ACROSS ANY VALVE**

**CONCLUSIONS :**

- NORMAL LV RV DIMENSION
- GOOD LV SYSTOLIC FUNCTION
- LVEF = 59 %
- NO RWMA
- ALL VALVES NORMAL
- NO CLOT / VEGETATION
- NO PERICARDIAL EFFUSION

**OPINION – NORMAL 2D-ECHO & COLOUR DOPPLER STUDY**

**DR. PANKAJ RASTOGI MD.DM**



Patient Name : Mr.ABDUL HALEEM  
Age/Gender : 60 Y/M  
**Lab No : 10135996**  
Referred By : Dr.GALAXY HOSPITAL  
Refer Lab/Hosp : CHARAK NA

Visit No : CHA250038701  
Registration ON : 04/Mar/2025 09: 28AM  
Sample Collected ON : 04/Mar/2025 09: 28AM  
Sample Received ON :  
Report Generated ON : 04/Mar/2025 11: 13AM

\*\*\* End Of Report \*\*\*

