

Patient Name	: Ms.SUFIYA	Visit No	: CHA250039441
Age/Gender	: 42 Y/F	Registration ON	: 05/Mar/2025 08:53AM
<b>Lab No</b>	<b>: 10136736</b>	Sample Collected ON	: 05/Mar/2025 08:53AM
Referred By	: Dr.SAMUDAIK SWASTH KENDRA	Sample Received ON	:
Refer Lab/Hosp	: CHARAK NA	Report Generated ON	: 05/Mar/2025 11:08AM

**2D- ECHO & COLOR DOPPLER REPORT**

1. MITRAL VALVE STUDY : MVOA - Normal (perimetry) cm2 (PHT)

**Anterior Mitral Leaflet:**

- (a) Motion: Normal (b) Thickness : Normal (c) DE : 1.7 cm.  
(d) EF : 103 mm/sec (e) EPSS : 06 mm (f) Vegetation : -  
(g) Calcium : -

**Posterior mitral leaflet : Normal**

- (a). Motion : Normal (b) Calcium: - (c) Vegetation : -  
Valve Score : Mobility /4 Thickness /4 SVA /4  
Calcium /4 Total /16

2. AORTIC VALVE STUDY

- (a) Aortic root : 2.6cms (b) Aortic Opening : 1.5cms (c) Closure: Central  
(d) Calcium : - (e) Eccentricity Index : 1 (f) Vegetation : -

(g) Valve Structure : Tricuspid,

3. PULMONARY VALVE STUDY

- (a) EF Slope : - (b) A Wave : + (c) MSN : -

- (D) Thickness : (e) Others :

4. TRICUSPID VALVE : Normal

5. SEPTAL AORTIC CONTINUITY 6. AORTIC MITRAL CONTINUITY

- Left Atrium : 3.3 cms Clot : - Others :  
Right Atrium : Normal Clot : - Others : -

Contd.....



Patient Name	: Ms.SUFIYA	Visit No	: CHA250039441
Age/Gender	: 42 Y/F	Registration ON	: 05/Mar/2025 08:53AM
<b>Lab No</b>	<b>: 10136736</b>	Sample Collected ON	: 05/Mar/2025 08:53AM
Referred By	: Dr.SAMUDAIK SWASTH KENDRA	Sample Received ON	:
Refer Lab/Hosp	: CHARAK NA	Report Generated ON	: 05/Mar/2025 11:08AM

VENTRICLES

**RIGHT VENTRICLE** : Normal

**RVD (D)**  
**RVOT**

**LEFT VENTRICLE** :

**LVIVS (D)** 0.7 cm (s) 1.3 cm

**Motion** : normal

**LVPW (D)** 0.8cm (s) 1.2 cm

**Motion** : Normal

**LVID (D)** 4.3 cm (s) 2.3 cm

**Ejection Fraction** : 77%

**Fractional Shortening** : 46 %

TOMOGRAPHIC VIEWS

**Parasternal Long axis view** :

NORMAL LV RV DIMENSION  
GOOD LV CONTRACTILITY.

**Short axis view**

**Aortic valve level** :

AOV - NORMAL  
**PV - NORMAL**  
TV - NORMAL

**Mitral valve level** :

MV - NORMAL

**Papillary Muscle Level** :

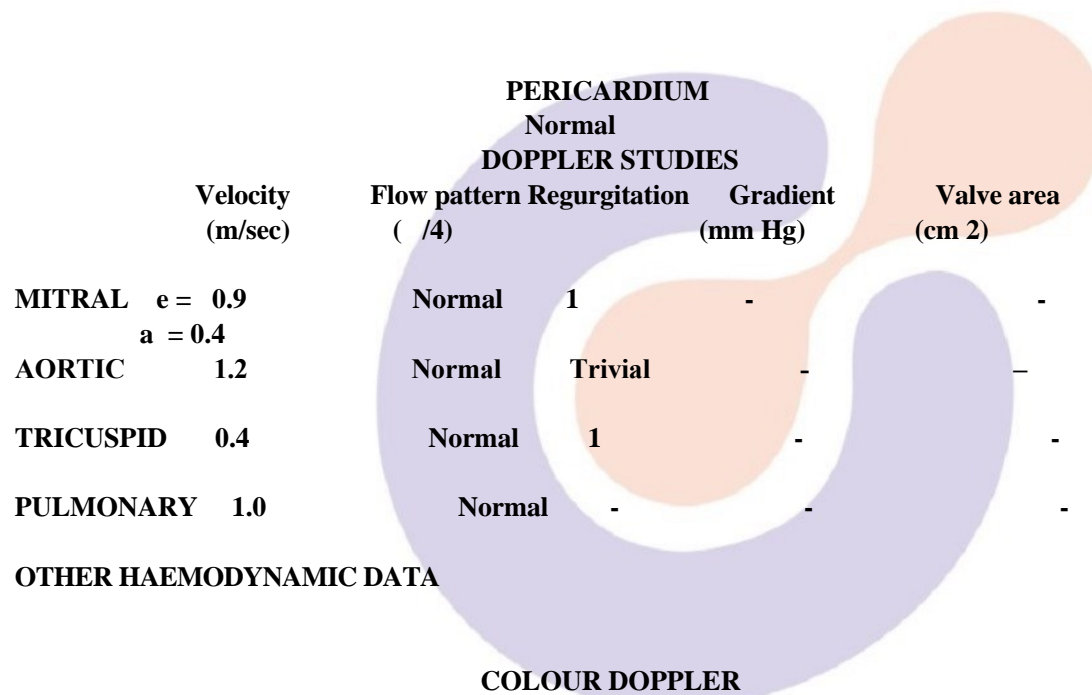
NO RWMA

**Apical 4 chamber View** :

No LV CLOT



Patient Name	: Ms.SUFIYA	Visit No	: CHA250039441
Age/Gender	: 42 Y/F	Registration ON	: 05/Mar/2025 08:53AM
<b>Lab No</b>	<b>: 10136736</b>	Sample Collected ON	: 05/Mar/2025 08:53AM
Referred By	: Dr.SAMUDAIK SWASTH KENDRA	Sample Received ON	:
Refer Lab/Hosp	: CHARAK NA	Report Generated ON	: 05/Mar/2025 11:08AM



GR I / IV MR  
GR I / IV TR  
TRIVIAL AR

**CHARAK**

**CONCLUSIONS :**

- NORMAL LV RV DIMENSION
- GOOD LV SYSTOLIC FUNCTION
- LVEF = 77 %
- NO RWMA
- MILD MR
- MILD TR
- TRIVIAL AR
- NO CLOT / VEGETATION
- NO PERICARDIAL EFFUSION

**DR. PANKAJ RASTOGI MD.DM**



Patient Name	: Ms.SUFIYA	Visit No	: CHA250039441
Age/Gender	: 42 Y/F	Registration ON	: 05/Mar/2025 08:53AM
<b>Lab No</b>	<b>: 10136736</b>	Sample Collected ON	: 05/Mar/2025 08:53AM
Referred By	: Dr.SAMUDAIK SWASTH KENDRA	Sample Received ON	:
Refer Lab/Hosp	: CHARAK NA	Report Generated ON	: 05/Mar/2025 11:08AM

\*\*\* End Of Report \*\*\*

