

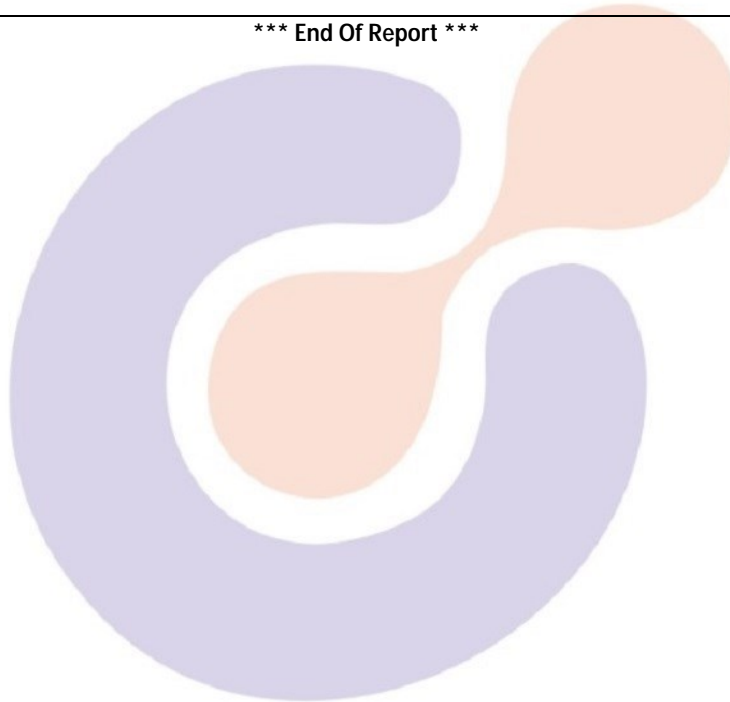
Patient Name : Ms.VANDNA SINGH
Age/Gender : 30 Y/F
Lab No : 10137552
Referred By : Dr.ESIC HOSPITAL LUCKNOW
Refer Lab/Hosp : ESIC HOSPITAL LUCKNOW
Doctor Advice : Coombs Indirect,USG TIFA STUDY

Visit No : CHA250040257
Registration ON : 06/Mar/2025 09:29AM
Sample Collected ON : 06/Mar/2025 09:30AM
Sample Received ON : 06/Mar/2025 09:34AM
Report Generated ON : 06/Mar/2025 11:50AM



Test Name	Result	Unit	Bio. Ref. Range	Method
Coombs Indirect				
Coombs Indirect	Negative		Negative	Tube agglutinat

*** End Of Report ***



CHARAK

[Checked By]

Print.Date/Time: 06-03-2025 12:25:08

*Patient Identity Has Not Been Verified. Not For Medicolegal



Sharma

DR. NISHANT SHARMA DR. SHADAB Dr. SYED SAIF AHMAD
PATHOLOGIST PATHOLOGIST MD (MICROBIOLOGY)

Patient Name	: Ms.VANDNA SINGH	Visit No	: CHA250040257
Age/Gender	: 30 Y/F	Registration ON	: 06/Mar/2025 09:29AM
Lab No	: 10137552	Sample Collected ON	: 06/Mar/2025 09:29AM
Referred By	: Dr.ESIC HOSPITAL LUCKNOW	Sample Received ON	:
Refer Lab/Hosp	: ESIC HOSPITAL LUCKNOW	Report Generated ON	: 06/Mar/2025 10:19AM

TARGETED IMAGING FOR FETAL ANOMALY (TIFFA)

- LMP : 19/10/2024, GA by LMP : 19 weeks + 5 days.
- Single live intrauterine foetus is seen in variable lie with biometric measurement of:
 - BPD 45 mm 19 weeks + 6 days
 - HC 161 mm 19 weeks + 0 days
 - BOD 29 mm 19 weeks + 2 days
 - AC 143 mm 19 weeks + 5 days
 - HL 28 mm 19 weeks + 2 days
 - ULNA 27 mm 19 weeks + 6 days
 - RADIUS 24 mm 19 weeks + 0 days
 - FL 31 mm 19 weeks + 4 days
 - TIB 25 mm 19 weeks + 1 days
 - FIB 29 mm 20 weeks + 3 days
- Mean gestational age is 19 weeks + 4 days (+/- 2 weeks).
- Foetal weight is approx. 301gms (\pm 44gms).
- EDD by CGA is approx. 27/07/2025 (on basis of present Sonographic age).
- Placenta is posterior wall. It shows grade I maturity. No evidence of retro placental collection.
- Amniotic fluid is adequate. DVP measures 4.0cm.
- Cervical length appears normal.

Foetal morphological characters

- Midline falx is seen. Foetal head shows normal cerebral ventricles. Anterior horn measures 4 mm. Posterior horn measures 7.5 mm. No evidence of hydrocephalus is noted. Cavum septum pellucidum and thalami normal. Posterior fossa shows normal bilateral cerebellar hemisphere. Cisterna magna is normal in size measuring 3.3 mm. Transcerebellar diameter 19 mm corresponding to 19 weeks 4 days. Nuchal fold measures 4 mm.

P.T.O



Patient Name	: Ms.VANDNA SINGH	Visit No	: CHA250040257
Age/Gender	: 30 Y/F	Registration ON	: 06/Mar/2025 09:29AM
Lab No	: 10137552	Sample Collected ON	: 06/Mar/2025 09:29AM
Referred By	: Dr.ESIC HOSPITAL LUCKNOW	Sample Received ON	:
Refer Lab/Hosp	: ESIC HOSPITAL LUCKNOW	Report Generated ON	: 06/Mar/2025 10:19AM

- Foetal face shows normal bilateral orbit with normal nose and lips, mandibular echo is seen normally. Nasal bone measures 5.4 mm.
- Foetal neck does not show any obvious mass lesion.
- Foetal spine appears normal in configuration. Cross sectional imaging shows normal trilaminar pattern. No evidence of mass / spina bifida is seen.
- Foetal chest shows normal heart lung ratio. Foetal heart shows normal position and ratio. 4 chamber foetal heart appears normal. No mass lesion is seen in chest. Bilateral diaphragms are normal.
- Foetal abdomen shows normal position of foetal stomach. Liver appears normal in position. Gall bladder is anechoic in lumen. Visualized bowel loops are normal. No evidence of abnormal dilatation / mass is seen in bowel.
- Foetal urinary bladder is moderately distended.
- Foetal both kidneys are normal in size, shape & echotexture. Both renal pelvises are normal.
- No evidence of dilated ureters is seen.
- Foetal umbilical cord is three vessels and shows normal insertion. No evidence of foetal abdominal wall defect is seen.
- Foetal limbs are normal. Bilateral femur, tibia and fibula, humerus and radius and ulna are normal in size.
- Bilateral foetal hands & feet are grossly normal.
- Foetal cardiac activity is regular, heart rate measuring 148/min.
- Foetal body and limb movements are well seen.

P.T.O



Patient Name	: Ms.VANDNA SINGH	Visit No	: CHA250040257
Age/Gender	: 30 Y/F	Registration ON	: 06/Mar/2025 09:29AM
Lab No	: 10137552	Sample Collected ON	: 06/Mar/2025 09:29AM
Referred By	: Dr.ESIC HOSPITAL LUCKNOW	Sample Received ON	:
Refer Lab/Hosp	: ESIC HOSPITAL LUCKNOW	Report Generated ON	: 06/Mar/2025 10:19AM

OPINION:

SINGLE LIVE FOETUS WITH MEAN GESTATION AGE OF 19 WEEKS + 4 DAYS (+/- 2 WEEKS) WITH NO APPARENT CONGENITAL MALFORMATION.

Note:-- I **Dr. Atima Srivastava**, declare that while conducting ultrasound study of **Mrs. Vandana Singh** I have neither detected nor disclosed the sex of her foetus to any body in any manner. All congenital anomalies can't be excluded on ultrasound.

- **Dedicated fetal 2D-echo is not a part of routine structural anomaly scan.**
- **Chromosomal / Genetic disorders cannot be ruled out by ultrasound.**
Clinical correlation is necessary.

**[DR. ATIMA SRIVASTAVA]
[MBBS, DNB (OBSTETRICS AND GYNAECOLOGY)]
[PDCC MATERNAL AND FETAL MEDICINE (SGPGIMS LUCKNOW)]**

NOTE :

- Ideal gestational age for TIFFA is between 18-20 weeks POG.
- Limitations of USG -
- USG has potency of detecting structural malformations in up to 60-70% of cases depending on the organ involved.
 - Functional abnormalities (behavior/ mind/hearing) in the fetus cannot be detected by USG.
 - Fetal hand and foot digits are difficult to count due to variable positions.
 - Conditions like trisomy 21 (Down syndrome) may have normal ultrasound findings in 60% cases as reporting in literature.
 - Serum screening (**double marker at 11-14 weeks/quadruple or triple test at 15-20 weeks**) will help in detecting more number of cases (**70% by triple test/87% by quadruple and 90% by double test**).
 - Few malformations develop late in intrauterine life and hence serial follow up scans are equaled to rule out their presence.
 - Subtle anomalies/malformations do not manifest in intrauterine life and may be detected postnatally for the first time.
 - Surgically correctable minor malformations (cleft/lip/palate/polydactyly) might be missed in USG.

Clinical correlation is necessary.

**[DR. ATIMA SRIVASTAVA]
[MBBS, DNB (OBSTETRICS AND GYNAECOLOGY)]
[PDCC MATERNAL AND FETAL MEDICINE (SGPGIMS LUCKNOW)]**

Transcribed By: Purvi

*** End Of Report ***

