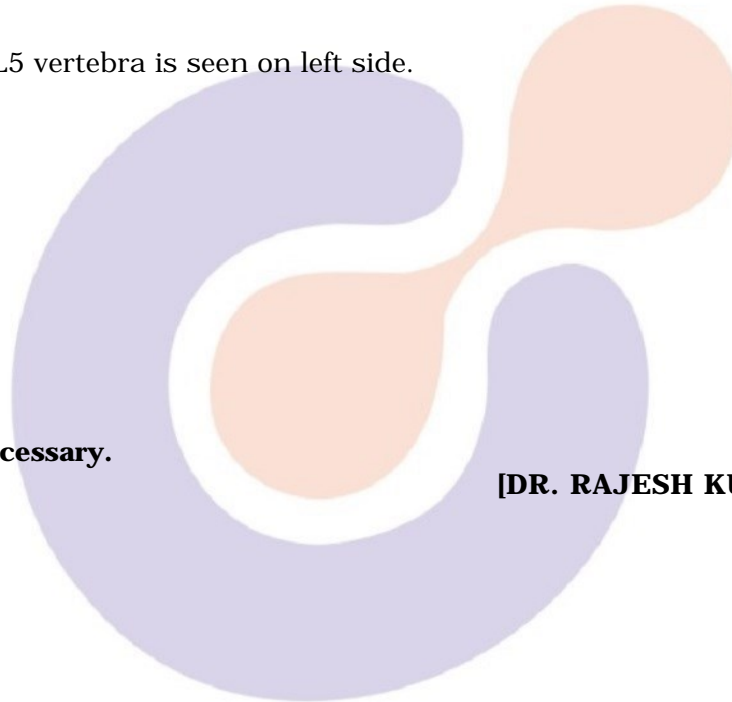


Patient Name	: Ms.JYOTI	Visit No	: CHA250040839
Age/Gender	: 27 Y/F	Registration ON	: 06/Mar/2025 07:45PM
Lab No	: 10138134	Sample Collected ON	: 06/Mar/2025 07:45PM
Referred By	: Dr.SAURABH AGARWAL	Sample Received ON	:
Refer Lab/Hosp	: CHARAK NA	Report Generated ON	: 07/Mar/2025 10:13AM

SKIAGRAM ABDOMEN (KUB) AP VIEW

- Radio opaque shadows are seen in left lumbar region and in pelvis of left side-----Renal and ureteric calculi.
- Partial sacralization of L5 vertebra is seen on left side.



Clinical correlation is necessary.

[DR. RAJESH KUMAR SHARMA, MD]

Transcribed by: Purvi

CHARAK



Patient Name	: Ms.JYOTI	Visit No	: CHA250040839
Age/Gender	: 27 Y/F	Registration ON	: 06/Mar/2025 07:45PM
Lab No	: 10138134	Sample Collected ON	: 06/Mar/2025 07:45PM
Referred By	: Dr.SAURABH AGARWAL	Sample Received ON	:
Refer Lab/Hosp	: CHARAK NA	Report Generated ON	: 07/Mar/2025 10:25AM

NCCT STUDY OF KUB

- **Right Kidney** is normal in size and position. No hydronephrosis is seen. Tiny faintly radio-opaque calculi are seen in middle & inferior calyces, measuring 2 mm to 3.2mm. No mass lesion is seen. Right kidney measures 92 x 43 mm.
- **Left Kidney** is normal in size and position. Mild hydronephrosis is seen. Radio-opaque calculi are seen in middle & inferior calyces measuring 3.0mm, 2.5mm & 4.5 mm (HU + 648). No mass lesion is seen. Left kidney measures 110 x 42 mm.
- **Both** left ureter is dilated & shows a radio-opaque calculus is distal part (just proximal to VUJ) measuring 7.1 mm (HU + 1264). Right ureter is normal in course and calibre.
- **Urinary Bladder** is normal in contour with normal lumen. No calculus or mass lesion is seen. UB walls are not thickened.
- **Uterus** is (retroverted) normal in size and shows homogenous myometrial density. No endometrial collection is seen. No mass lesion is seen.
- **Cervix** is normal.
- Right ovary shows cystic area measuring 33 x 29 mm.
- Left ovary is normal.
- No adnexal mass lesion is seen.
- Minimal free fluid is seen in Cul-de-Sac.

IMPRESSION:

- **BILATERAL SMALL RENAL CALCULI WITH LEFT DISTAL URETERIC CALCULUS WITH MILD HYDROURETERONEPHROSIS LEFT.**
- **SMALL RIGHT OVARIAN CYST - FUNCTIONAL CYST.**
- **MINIMAL FREE FLUID IN CUL-DE-SAC - INFLAMMATORY.**

Clinical correlation is necessary.

[DR. RAJESH KUMAR SHARMA, MD]

Transcribed by Priyanka...

*** End Of Report ***

