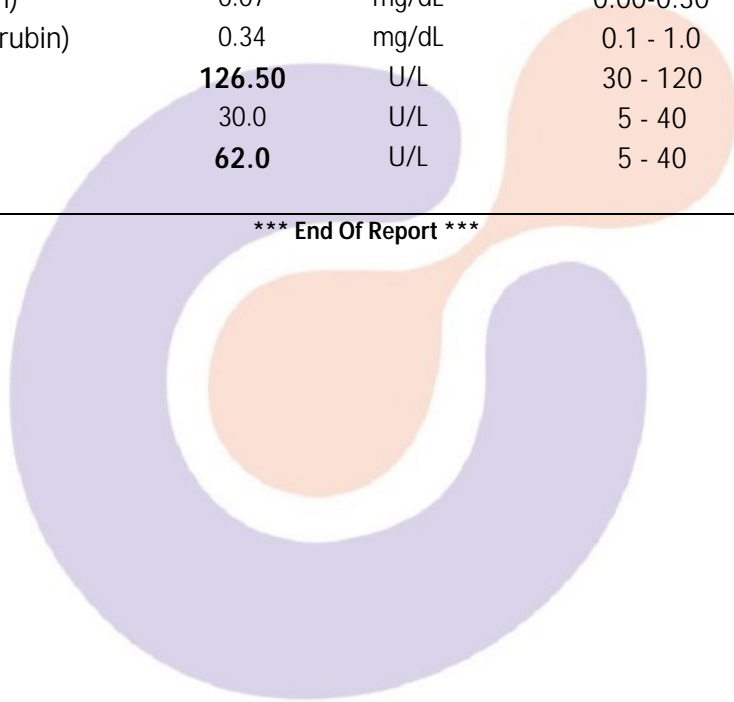


Patient Name : Ms.FARZANA	Visit No : CHA250040906
Age/Gender : 50 Y/F	Registration ON : 07/Mar/2025 07:40AM
Lab No : 10138201	Sample Collected ON : 07/Mar/2025 09:36AM
Referred By : Dr.WE CARE HOSPITAL	Sample Received ON : 07/Mar/2025 09:56AM
Refer Lab/Hosp : CHARAK NA	Report Generated ON : 07/Mar/2025 10:43AM
Doctor Advice : LFT,USG WHOLE ABDOMEN	



Test Name	Result	Unit	Bio. Ref. Range	Method
LIVER FUNCTION TEST				
TOTAL BILIRUBIN	0.41	mg/dl	0.4 - 1.1	Diazonium Ion
CONJUGATED (D. Bilirubin)	0.07	mg/dL	0.00-0.30	Diazotization
UNCONJUGATED (I.D. Bilirubin)	0.34	mg/dL	0.1 - 1.0	Calculated
ALK PHOS	126.50	U/L	30 - 120	PNPP, AMP Buffer
SGPT	30.0	U/L	5 - 40	UV without P5P
SGOT	62.0	U/L	5 - 40	UV without P5P

*** End Of Report ***



CHARAK



[Checked By]



Sham

DR. NISHANT SHARMA
PATHOLOGIST

DR. SHADAB
PATHOLOGIST

Dr. SYED SAIF AHMAD
MD (MICROBIOLOGY)

Patient Name : Ms.FARZANA Visit No : CHA250040906
Age/Gender : 50 Y/F Registration ON : 07/Mar/2025 07:40AM
Lab No : 10138201 Sample Collected ON : 07/Mar/2025 07:40AM
Referred By : Dr.WE CARE HOSPITAL Sample Received ON :
Refer Lab/Hosp : CHARAK NA Report Generated ON : 07/Mar/2025 09:45AM

ULTRASOUND STUDY OF WHOLE ABDOMEN

Excessive gaseous abdomen

- **Liver** is mildly enlarged in size (~153mm) and shows increased echotexture of liver parenchyma. No intrahepatic biliary radicle dilatation is seen. No space occupying lesion is seen. Hepatic veins and IVC are seen normally.
- **Gall bladder** is not visualized (post operative).
- **CBD** is normal at porta. No obstructive lesion is seen.
- **Portal vein** Portal vein is normal at porta.
- **Pancreas** is normal in size and shows homogenous echotexture of parenchyma. PD is not dilated. No parenchymal calcification is seen. No peripancreatic collection is seen.
- **Spleen** is normal in size and shows homogenous echotexture of parenchyma. No SOL is seen.
- No retroperitoneal adenopathy is seen.
- No ascites is seen.
- **Both kidneys** are normal in size and position. No hydronephrosis is seen. **Simple cortical cyst is seen at lower pole of right kidney measuring approx 11 x 11mm.** No calculus is seen. Cortico-medullary differentiation is well maintained. Parenchymal thickness is normal. No scarring is seen. Right kidney measures 104 x 43 mm in size. Left kidney measures 104 x 44 mm in size.
- **Ureters** Both ureters are not dilated. UVJ are seen normally.
- **Urinary bladder** is normal in contour with anechoic lumen. No calculus or mass lesion is seen. UB walls are not thickened.
- **Uterus** is atrophic. Endometrial thickness measures 2.0mm.
- No adnexal mass lesion is seen.

OPINION:

- MILD HEPATOMEGALY WITH FATTY INFILTRATION OF LIVER GRADE-I.
- SIMPLE RIGHT RENAL CORTICAL CYST.

(Possibility of acid peptic disease could not be ruled out).

Clinical correlation is necessary.

(DR. R.K. SINGH, MD)

Transcribed by Gausiya

*** End Of Report ***

