

Patient Name	: Ms.NASREEN	Visit No	: CHA250041069
Age/Gender	: 51 Y/F	Registration ON	: 07/Mar/2025 11:13AM
Lab No	: 10138364	Sample Collected ON	: 07/Mar/2025 11:13AM
Referred By	: Dr.U1	Sample Received ON	:
Refer Lab/Hosp	: CHARAK NA	Report Generated ON	: 07/Mar/2025 12:31PM

2D- ECHO & COLOR DOPPLER REPORT

1. MITRAL VALVE STUDY : MVOA - Normal (perimetry) cm2 (PHT)

Anterior Mitral Leaflet:

- (a) Motion: Normal (b) Thickness : Normal (c) DE : 1.7 cm.
(d) EF : 82 mm/sec (e) EPSS : 06 mm (f) Vegetation : -
(g) Calcium : -

Posterior mitral leaflet : Normal

- (a). Motion : Normal (b) Calcium: - (c) Vegetation : -
Valve Score : Mobility /4 Thickness /4 SVA /4
Calcium /4 Total /16

2. AORTIC VALVE STUDY

- (a) Aortic root : 2.3cms (b) Aortic Opening : 1.8cms (c) Closure: Central
(d) Calcium : - (e) Eccentricity Index : 1 (f) Vegetation : -
(g) Valve Structure : Tricuspid, Normal

3. PULMONARY VALVE STUDY

- (a) EF Slope : - (b) A Wave : + (c) MSN : -
(D) Thickness : (e) Others :

4. TRICUSPID VALVE : Normal

5. SEPTAL AORTIC CONTINUITY 6. AORTIC MITRAL CONTINUITY

- Left Atrium : 3.3 cms Clot : - Others :
Right Atrium : Normal Clot : - Others : -

Contd.....



Patient Name	: Ms.NASREEN	Visit No	: CHA250041069
Age/Gender	: 51 Y/F	Registration ON	: 07/Mar/2025 11:13AM
Lab No	: 10138364	Sample Collected ON	: 07/Mar/2025 11:13AM
Referred By	: Dr.U1	Sample Received ON	:
Refer Lab/Hosp	: CHARAK NA	Report Generated ON	: 07/Mar/2025 12:31PM

VENTRICLES

RIGHT VENTRICLE : Normal

RVD (D)
RVOT

LEFT VENTRICLE :

LVIVS (D) 0.8 cm (s) 1.1 cm

LVPW (D) 1.1cm (s) 1.4 cm

LVID (D) 4.0 cm (s) 2.2cm

Motion : normal

Motion : Normal

Ejection Fraction :77%

Fractional Shortening : 45 %

TOMOGRAPHIC VIEWS

Parasternal Long axis view :

NORMAL LV RV DIMENSION
GOOD LV CONTRACTILITY.

Short axis view

Aortic valve level :

AOV - NORMAL
PV - NORMAL
TV - NORMAL

Mitral valve level :

MV - NORMAL

Papillary Muscle Level :

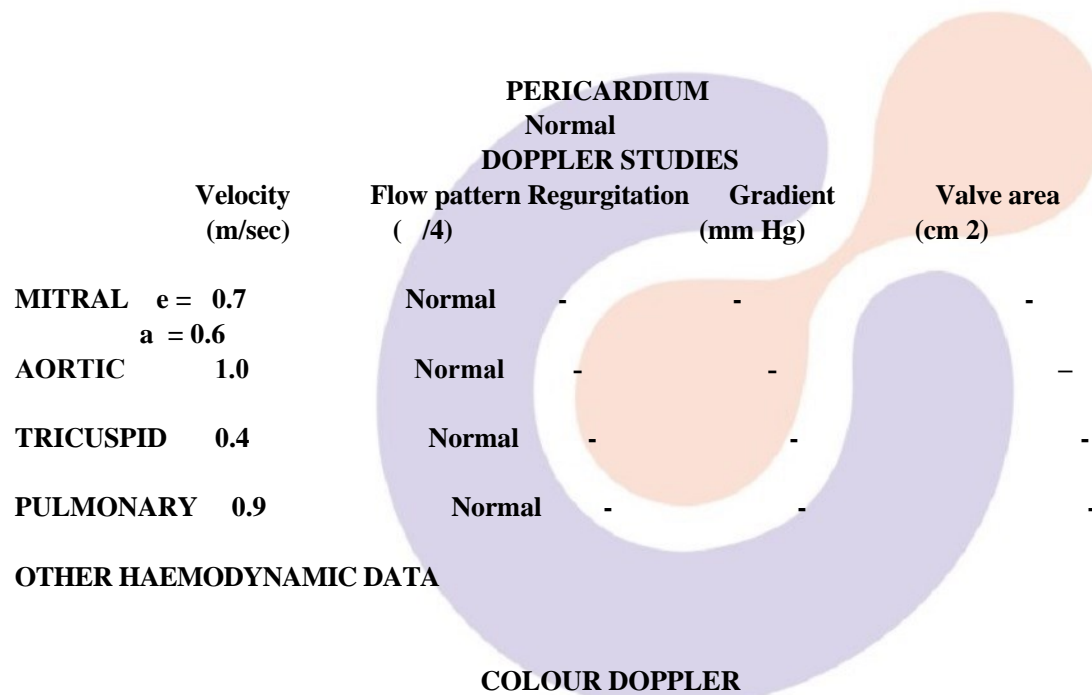
NO RWMA

Apical 4 chamber View :

No LV CLOT



Patient Name	: Ms.NASREEN	Visit No	: CHA250041069
Age/Gender	: 51 Y/F	Registration ON	: 07/Mar/2025 11:13AM
Lab No	: 10138364	Sample Collected ON	: 07/Mar/2025 11:13AM
Referred By	: Dr.U1	Sample Received ON	:
Refer Lab/Hosp	: CHARAK NA	Report Generated ON	: 07/Mar/2025 12:31PM



NO REGURGITATION OR TURBULENCE ACROSS ANY VALVE

CONCLUSIONS :

- NORMAL LV RV DIMENSION
- GOOD LV SYSTOLIC FUNCTION
- LVEF = 77 %
- NO RWMA
- ALL VALVES NORMAL
- NO CLOT / VEGETATION
- NO PERICARDIAL EFFUSION

OPINION – NORMAL 2D-ECHO & COLOUR DOPPLER STUDY

DR. PANKAJ RASTOGI MD.DM



Patient Name	: Ms.NASREEN	Visit No	: CHA250041069
Age/Gender	: 51 Y/F	Registration ON	: 07/Mar/2025 11:13AM
Lab No	: 10138364	Sample Collected ON	: 07/Mar/2025 11:13AM
Referred By	: Dr.U1	Sample Received ON	:
Refer Lab/Hosp	: CHARAK NA	Report Generated ON	: 07/Mar/2025 12:31PM

*** End Of Report ***

