

Patient Name : Mr.RAM PARVESH SINGH	Visit No : CHA250041620
Age/Gender : 67 Y/M	Registration ON : 08/Mar/2025 10:00AM
Lab No : 10138915	Sample Collected ON : 08/Mar/2025 10:05AM
Referred By : Dr.KRISHNA KUMAR MITRA (CGHS)	Sample Received ON : 08/Mar/2025 10:05AM
Refer Lab/Hosp : CGHS (BILLING)	Report Generated ON : 08/Mar/2025 02:02PM
Doctor Advice : USG WHOLE ABDOMEN, URINE C/S, URINE COM. EXAMINATION, PLAT COUNT, SGPT	



Test Name	Result	Unit	Bio. Ref. Range	Method
-----------	--------	------	-----------------	--------

URINE EXAMINATION REPORT

Colour-U	STRAW		Light Yellow	
Appearance (Urine)	CLEAR		Clear	
Specific Gravity	1.015		1.005 - 1.025	
pH-Urine	Acidic (6.0)		4.5 - 8.0	
PROTEIN	Absent	mg/dl	ABSENT	Dipstick
Glucose	Absent			
Ketones	Absent		Absent	
Bilirubin-U	Absent		Absent	
Blood-U	Absent		Absent	
Urobilinogen-U	0.20	EU/dL	0.2 - 1.0	
Leukocytes-U	Absent		Absent	
NITRITE	Absent		Absent	
MICROSCOPIC EXAMINATION				
Pus cells / hpf	Occasional	/hpf	< 5/hpf	
Epithelial Cells	Occasional	/hpf	0 - 5	
RBC / hpf	Nil		< 3/hpf	

CHARAK

[Checked By]



Print.Date/Time: 08-03-2025 14:41:32

*Patient Identity Has Not Been Verified. Not For Medicolegal

DR. NISHANT SHARMA
PATHOLOGIST

DR. SHADAB
PATHOLOGIST

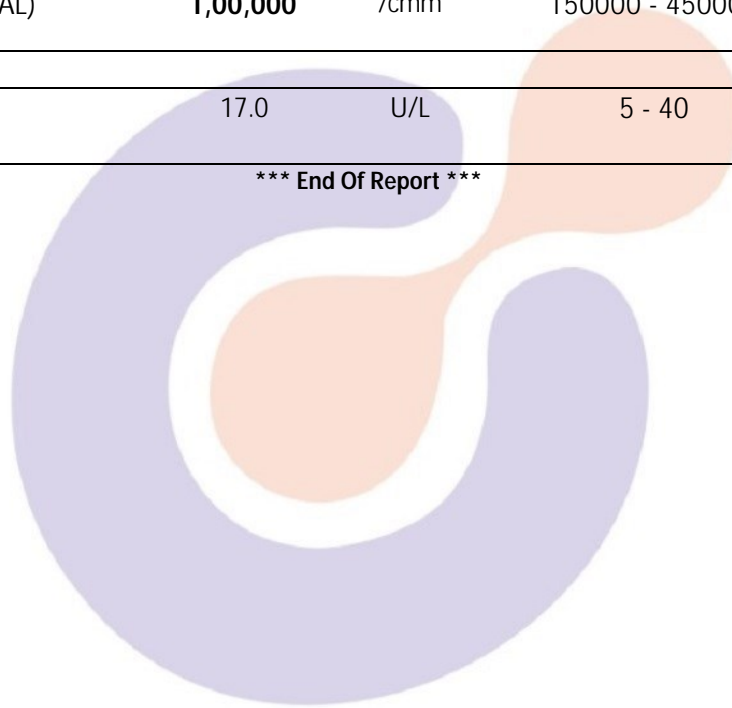
Aditi D Agarwal
DR. ADITI D AGARWAL
PATHOLOGIST

Patient Name : Mr. RAM PARVESH SINGH	Visit No : CHA250041620
Age/Gender : 67 Y/M	Registration ON : 08/Mar/2025 10:00AM
Lab No : 10138915	Sample Collected ON : 08/Mar/2025 10:05AM
Referred By : Dr. KRISHNA KUMAR MITRA (CGHS)	Sample Received ON : 08/Mar/2025 10:14AM
Refer Lab/Hosp : CGHS (BILLING)	Report Generated ON : 08/Mar/2025 10:44AM
Doctor Advice : USG WHOLE ABDOMEN, URINE C/S, URINE COM. EXMAMINATION, PLAT COUNT, SGPT	



Test Name	Result	Unit	Bio. Ref. Range	Method
PLATELET COUNT				
PLATELET COUNT	80,000	/cmm	150000 - 450000	Elect Imped..
PLATELET COUNT (MANUAL)	1,00,000	/cmm	150000 - 450000	Microscopy .
SGPT				
SGPT	17.0	U/L	5 - 40	UV without P5P

*** End Of Report ***



CHARAK



MC-2491

Print.Date/Time: 08-03-2025 14:41:34

*Patient Identity Has Not Been Verified. Not For Medicolegal



Sham

DR. NISHANT SHARMA
PATHOLOGIST

DR. SHADAB
PATHOLOGIST

Dr. SYED SAIF AHMAD
MD (MICROBIOLOGY)

Patient Name	: Mr.RAM PARVESH SINGH	Visit No	: CHA250041620
Age/Gender	: 67 Y/M	Registration ON	: 08/Mar/2025 10:00AM
Lab No	: 10138915	Sample Collected ON	: 08/Mar/2025 10:00AM
Referred By	: Dr.KRISHNA KUMAR MITRA (CGHS)	Sample Received ON	:
Refer Lab/Hosp	: CGHS (BILLING)	Report Generated ON	: 08/Mar/2025 10:55AM

ULTRASOUND STUDY OF WHOLE ABDOMEN

- **Liver** is mildly enlarged in size (~149mm) and shows increased echotexture of liver parenchyma. A well defined anechoic cyst of size approx 15 x 14mm is noted in segment IV of liver. No intrahepatic biliary radicle dilatation is seen. Hepatic veins and IVC are seen normally.
- **Gall bladder** is normal in size and shows a small echogenic focus of size approx 4.0mm floating in GB lumen with subtle acoustic shadowing. No mass lesion is seen. GB walls are not thickened.
- **CBD** is normal at porta. No obstructive lesion is seen.
- **Portal vein** Portal vein is normal at porta.
- **Pancreas** is normal in size and shows homogenous echotexture of parenchyma. PD is not dilated. No parenchymal calcification is seen. No peripancreatic collection is seen.
- **Spleen** is normal in size and shows homogenous echotexture of parenchyma. No SOL is seen.
- No retroperitoneal adenopathy is seen.
- No ascites is seen.
- **Both kidneys** are normal in size and position. No hydronephrosis is seen. No calculus or mass lesion is seen. Cortico-medullary differentiation is well maintained. Parenchymal thickness is normal. No scarring is seen. Right kidney measures 91 x 47 mm in size. Left kidney measures 96 x 51 mm in size.
- **Ureters** Both ureters are not dilated. UVJ are seen normally.
- **Urinary bladder** is normal in contour with anechoic lumen. No calculus or mass lesion is seen. UB walls are not thickened.
- Bilateral seminal vesicles are seen normally.
- **Prostate** is enlarged in size, measures 39 x 37 x 37 mm with weight of 28gms and shows homogenous echotexture of parenchyma. No mass lesion is seen.

OPINION:

- MILD HEPATOMEGALY WITH FATTY INFILTRATION OF LIVER GRADE-I.
- SIMPLE HEPATIC CYST IN SEGMENT IV OF LIVER.
- A SMALL ECHOGENIC FOCUS FLOATING IN GB LUMEN WITH SUBTLE ACOUSTIC SHADOWING - SOFT CALCULUS / MICRO-CHOLELITHIASIS (ADV: FOLLOW UP).
- PROSTATOMEGALY GRADE-I.

Clinical correlation is necessary.

[DR. R. K. SINGH, MD]

Transcribed by Gausiya



Patient Name	: Mr.RAM PARVESH SINGH	Visit No	: CHA250041620
Age/Gender	: 67 Y/M	Registration ON	: 08/Mar/2025 10:00AM
Lab No	: 10138915	Sample Collected ON	: 08/Mar/2025 10:00AM
Referred By	: Dr.KRISHNA KUMAR MITRA (CGHS)	Sample Received ON	:
Refer Lab/Hosp	: CGHS (BILLING)	Report Generated ON	: 08/Mar/2025 10:55AM

*** End Of Report ***

