

Patient Name : Ms. PRAMILA DEVI	Visit No : CHA250038051
Age/Gender : 35 Y/F	Registration ON : 03/Mar/2025 11:24AM
<b>Lab No : 10135346</b>	Sample Collected ON : 03/Mar/2025 11:30AM
Referred By : Dr. HEALTH POINT	Sample Received ON : 03/Mar/2025 11:52AM
Refer Lab/Hosp : CHARAK NA	Report Generated ON : 09/Mar/2025 09:44AM
Doctor Advice : BIOPSY (H/P)	



**BIOPSY**

**498/25 HISTOPATHOLOGY EXAMINATION REPORT**

**SPECIMEN: GALL BLADDER**

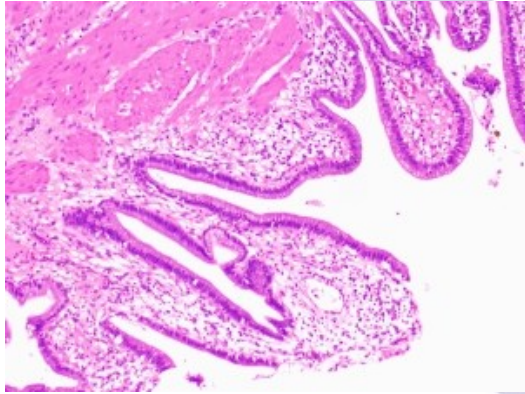
**GROSS:**

Received as opened up gall bladder specimen measuring 8.0x2.5 cm. Outer surface is smooth and congested. Cuts firm. Cut surface shows bile-stained velvety mucosa. Wall thickness varies from 0.2-0.5 cm. Stones present. Partially embedded.

**MICROSCOPY:**

Section 498/25 shows partially denuded mucosa lined by tall columnar epithelium. Rokitansky aschoff's sinus is seen. There is mild panmural chronic inflammatory cell infiltrate along with hypertrophied muscularis propria.

There is no evidence of malignancy.



**DIAGNOSIS:**

**CHRONIC CHOLECYSTITIS WITH CHOLELITHIASIS.**

[Checked By]

Print.Date/Time: 09-03-2025 10:23:14

\*Patient Identity Has Not Been Verified. Not For Medicolegal



*Brijender Singh*  
Dr. Brijender singh  
MD (Path)

Patient Name	: Ms.PRAMILA DEVI	Visit No	: CHA250038051
Age/Gender	: 35 Y/F	Registration ON	: 03/Mar/2025 11:24AM
<b>Lab No</b>	<b>: 10135346</b>	Sample Collected ON	: 03/Mar/2025 11:30AM
Referred By	: Dr.HEALTH POINT	Sample Received ON	: 03/Mar/2025 11:52AM
Refer Lab/Hosp	: CHARAK NA	Report Generated ON	: 09/Mar/2025 09:44AM
Doctor Advice	: BIOPSY (H/P)		



\*\*\* End Of Report \*\*\*



[Checked By]

Print.Date/Time: 09-03-2025 10:23:15

\*Patient Identity Has Not Been Verified. Not For Medicolegal



*Brijender Singh*

Dr. Brijender singh  
MD (Path)