

Patient Name : Mr. ANURAG SINGH GAUTAM	Visit No : CHA250038052
Age/Gender : 41 Y/M	Registration ON : 03/Mar/2025 11:25AM
Lab No : 10135347	Sample Collected ON : 03/Mar/2025 11:30AM
Referred By : Dr. HEALTH POINT	Sample Received ON : 03/Mar/2025 11:52AM
Refer Lab/Hosp : CHARAK NA	Report Generated ON : 09/Mar/2025 09:43AM
Doctor Advice : BIOPSY (H/P)	



**BIOPSY**

**496/25 HISTOPATHOLOGY EXAMINATION REPORT**

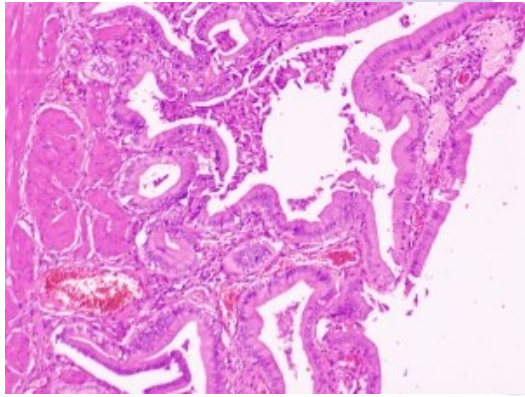
**SPECIMEN: GALL BLADDER**

**GROSS:** Received opened up gall bladder measuring 9.0x2.5 cm. Outer surface is smooth and congested. Cuts firm. Cut surface shows partially atrophied mucosa. Wall thickness varies from 0.3 cm to 0.5 cm. Stones are identified. Partially embedded.

**MICROSCOPY:**

Section 496/25 shows partially denuded mucosa lined by tall columnar epithelium. Rokitansky aschoff's sinus are seen. Lamina propria shows collection of foamy histiocytes. There is mild panmural chronic inflammatory cell infiltrate along with few mucosal glands entrapped within muscularis layer. One bit shows foreign body giant cell reaction against impacted stone.

There is no evidence of malignancy.



**DIAGNOSIS: CHRONIC CHOLECYSTITIS WITH CHOLESTEROLOSIS & CHOLELITHIASIS.**

\*\*\* End Of Report \*\*\*

[Checked By]

Print.Date/Time: 09-03-2025 10:17:30

\*Patient Identity Has Not Been Verified. Not For Medicolegal



*Brijender Singh*  
Dr. Brijender singh  
MD (Path)