

Patient Name : Mr. BABLU KUMAR	Visit No : CHA250038348
Age/Gender : 27 Y/M	Registration ON : 03/Mar/2025 03: 35PM
<b>Lab No : 10135643</b>	Sample Collected ON : 03/Mar/2025 03: 37PM
Referred By : Dr.RML	Sample Received ON : 03/Mar/2025 03: 43PM
Refer Lab/Hosp : CHARAK NA	Report Generated ON : 09/Mar/2025 09: 45AM
Doctor Advice : BIOPSY (H/P)	



**BIOPSY**

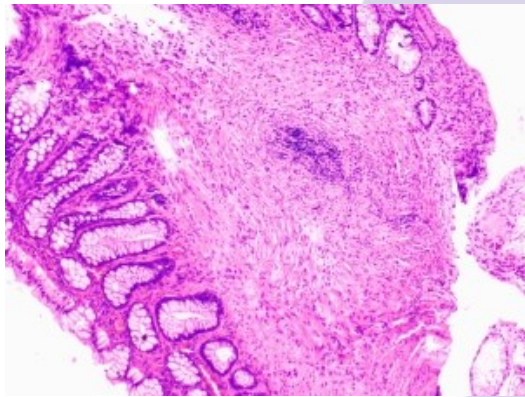
**499/25 HISTOPATHOLOGY EXAMINATION REPORT**

**SPECIMEN: BIOPSY FROM RECTUM.**

**GROSS:** Received multiple grayish white soft tissue pieces collectively measuring 0.5 cm. All embedded.

**MICROSCOPY:** Section 499/25 shows biopsy tissue lined by ulcerated mucosa along with fibromuscular hyperplasia of lamina propria, crypts elongation and splayed fibers of muscularis mucosa. There is mild chronic inflammatory cells infiltrate into lamina propria.

There is no evidence of malignancy.



**DIAGNOSIS:** Histomorphology is suggestive of **SOLITARY RECTAL ULCER SYNDROME.**

CHARAK

\*\*\* End Of Report \*\*\*

[Checked By]

Print.Date/Time: 09-03-2025 10:23:10

\*Patient Identity Has Not Been Verified. Not For Medicolegal



*Brijender Singh*

Dr. Brijender singh  
MD (Path)