

Patient Name	: Ms.SUSHEELA	Visit No	: CHA250042274
Age/Gender	: 32 Y/F	Registration ON	: 09/Mar/2025 09:45AM
Lab No	: 10139569	Sample Collected ON	: 09/Mar/2025 09:45AM
Referred By	: Dr.RN BAJPAI	Sample Received ON	:
Refer Lab/Hosp	: CHARAK NA	Report Generated ON	: 09/Mar/2025 10:55AM

2D- ECHO & COLOR DOPPLER REPORT

1. MITRAL VALVE STUDY : MVOA - Normal (perimetry) cm2 (PHT)

Anterior Mitral Leaflet:

- (a) Motion: Normal (b) Thickness : Normal (c) DE : 1.5cm.
(d) EF 98 mm/sec (e) EPSS : 06 mm (f) Vegetation : -
(g) Calcium : -

Posterior mitral leaflet : Normal

- (a). Motion : Normal (b) Calcium: - (c) Vegetation : -
Valve Score : Mobility /4 Thickness /4 SVA /4
Calcium /4 Total /16

2. AORTIC VALVE STUDY

- (a) Aortic root :3.1cms (b) Aortic Opening :1.9cms (c) Closure: Central
(d) Calcium : - (e) Eccentricity Index : 1 (f) Vegetation : -
(g) Valve Structure : Tricuspid, Normal

3. PULMONARY VALVE STUDY

- (a) EF Slope : - (b) A Wave : + (c) MSN : -
(D) Thickness : (e) Others :

4. TRICUSPID VALVE : Normal

5. SEPTAL AORTIC CONTINUITY 6. AORTIC MITRAL CONTINUITY

- Left Atrium : 2.1 cms Clot : - Others :
Right Atrium : Normal Clot : - Others : -

Contd.....



Patient Name	: Ms.SUSHEELA	Visit No	: CHA250042274
Age/Gender	: 32 Y/F	Registration ON	: 09/Mar/2025 09: 45AM
Lab No	: 10139569	Sample Collected ON	: 09/Mar/2025 09: 45AM
Referred By	: Dr.RN BAJPAI	Sample Received ON	:
Refer Lab/Hosp	: CHARAK NA	Report Generated ON	: 09/Mar/2025 10: 55AM

VENTRICLES

RIGHT VENTRICLE : Normal

RVD (D)
RVOT

LEFT VENTRICLE :

LVIVS (D) 0.7 cm (s) 1.0 cm

Motion : normal

LVPW (D) 0.9cm (s) 1.4 cm

Motion : Normal

LVID (D) 4.1 cm (s) 2.5 cm

Ejection Fraction :68%

Fractional Shortening : 38 %

TOMOGRAPHIC VIEWS

Parasternal Long axis view :

NORMAL LV RV DIMENSION
GOOD LV CONTRACTILITY.

Short axis view

Aortic valve level :

AOV - NORMAL
PV - NORMAL
TV - NORMAL

Mitral valve level :

MV - NORMAL

Papillary Muscle Level :

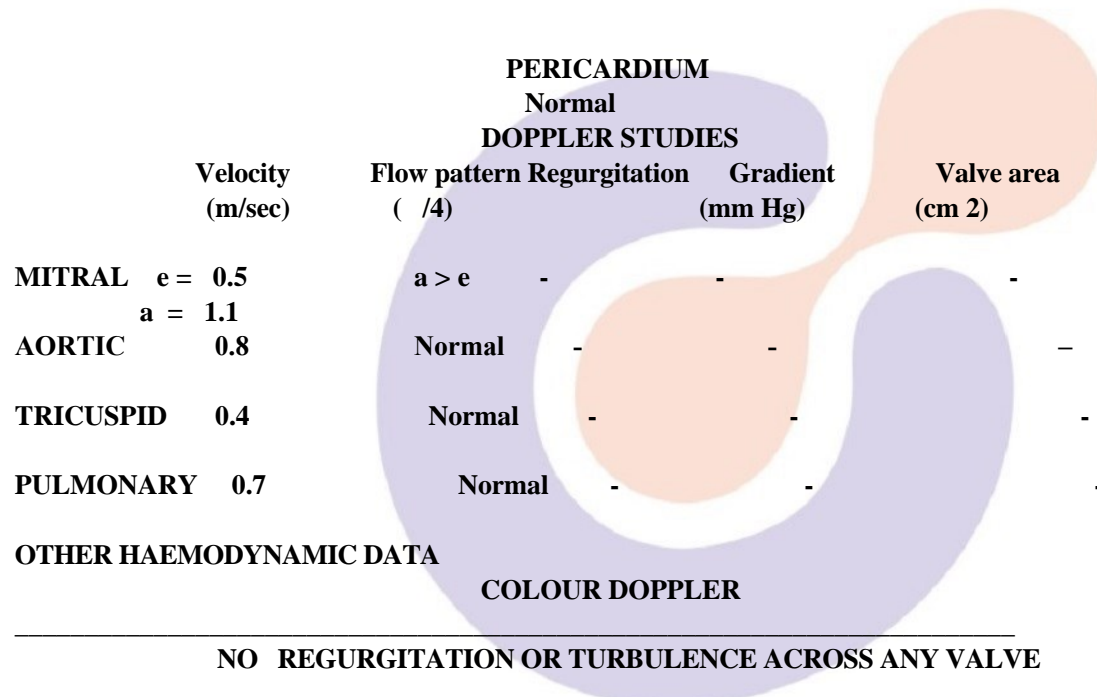
NO RWMA

Apical 4 chamber View :

No LV CLOT



Patient Name	: Ms.SUSHEELA	Visit No	: CHA250042274
Age/Gender	: 32 Y/F	Registration ON	: 09/Mar/2025 09: 45AM
Lab No	: 10139569	Sample Collected ON	: 09/Mar/2025 09: 45AM
Referred By	: Dr.RN BAJPAI	Sample Received ON	:
Refer Lab/Hosp	: CHARAK NA	Report Generated ON	: 09/Mar/2025 10: 55AM



- CONCLUSIONS :**
- NORMAL LV RV DIMENSION
 - GOOD LV SYSTOLIC FUNCTION
 - LVEF = 68 %
 - NO RWMA
 - a > e
 - NO CLOT / VEGETATION
 - NO PERICARDIAL EFFUSION

DR. PANKAJ RASTOGI, MD,DM

*** End Of Report ***

