

Patient Name	: Mr. BECHE LAL	Visit No	: CHA250042701
Age/Gender	: 56 Y O M O D /M	Registration ON	: 10/Mar/2025 08:13AM
Lab No	: 10139996	Sample Collected ON	: 10/Mar/2025 08:13AM
Referred By	: Dr.CIVIL HOSPITAL	Sample Received ON	:
Refer Lab/Hosp	: CHARAK NA	Report Generated ON	: 10/Mar/2025 11:06AM

2D- ECHO & COLOR DOPPLER REPORT

1. **MITRAL VALVE STUDY** : MVOA - Normal (perimetry) cm2 (PHT)

Anterior Mitral Leaflet:

- (a) Motion: Normal (b) Thickness : Normal (c) DE : 1.9 cm.
(d) EF : 74 mm/sec (e) EPSS : 06 mm (f) Vegetation : -
(g) Calcium : -

Posterior mitral leaflet : Normal

- (a). Motion : Normal (b) Calcium: - (c) Vegetation : -
Valve Score : Mobility /4 Thickness /4 SVA /4
Calcium /4 Total /16

2. **AORTIC VALVE STUDY**

- (a) Aortic root : 3.5cms (b) Aortic Opening : 2.0cms (c) Closure: Central
(d) Calcium : - (e) Eccentricity Index : 1 (f) Vegetation : -
(g) Valve Structure : Tricuspid, Normal

3. **PULMONARY VALVE STUDY**

- (a) EF Slope : - (b) A Wave : + (c) MSN : -
(D) Thickness : (e) Others :

4. **TRICUSPID VALVE :** Normal

5. **SEPTAL AORTIC CONTINUITY** 6. **AORTIC MITRAL CONTINUITY**

- Left Atrium : 5.0 cms Clot : - Others :
Right Atrium : Normal Clot : - Others : -

Contd.....



Patient Name	: Mr. BECHE LAL	Visit No	: CHA250042701
Age/Gender	: 56 Y O M O D /M	Registration ON	: 10/Mar/2025 08:13AM
Lab No	: 10139996	Sample Collected ON	: 10/Mar/2025 08:13AM
Referred By	: Dr.CIVIL HOSPITAL	Sample Received ON	:
Refer Lab/Hosp	: CHARAK NA	Report Generated ON	: 10/Mar/2025 11:06AM

VENTRICLES

RIGHT VENTRICLE : Normal

RVD (D)
RVOT

LEFT VENTRICLE :

LVIVS (D) 1.4 cm (s) 1.9 cm

Motion : normal

LVPW (D) 1.6cm (s) 2.1 cm

Motion : Normal

LVID (D) 4.9 cm (s) 2.9 cm

Ejection Fraction :72%

Fractional Shortening : 41%

TOMOGRAPHIC VIEWS

Parasternal Long axis view :

CONCENTRIC LVH
GOOD LV CONTRACTILITY.

Short axis view

Aortic valve level :

AOV - NORMAL
PV - NORMAL
TV - NORMAL

Mitral valve level :

MV - NORMAL

Papillary Muscle Level :

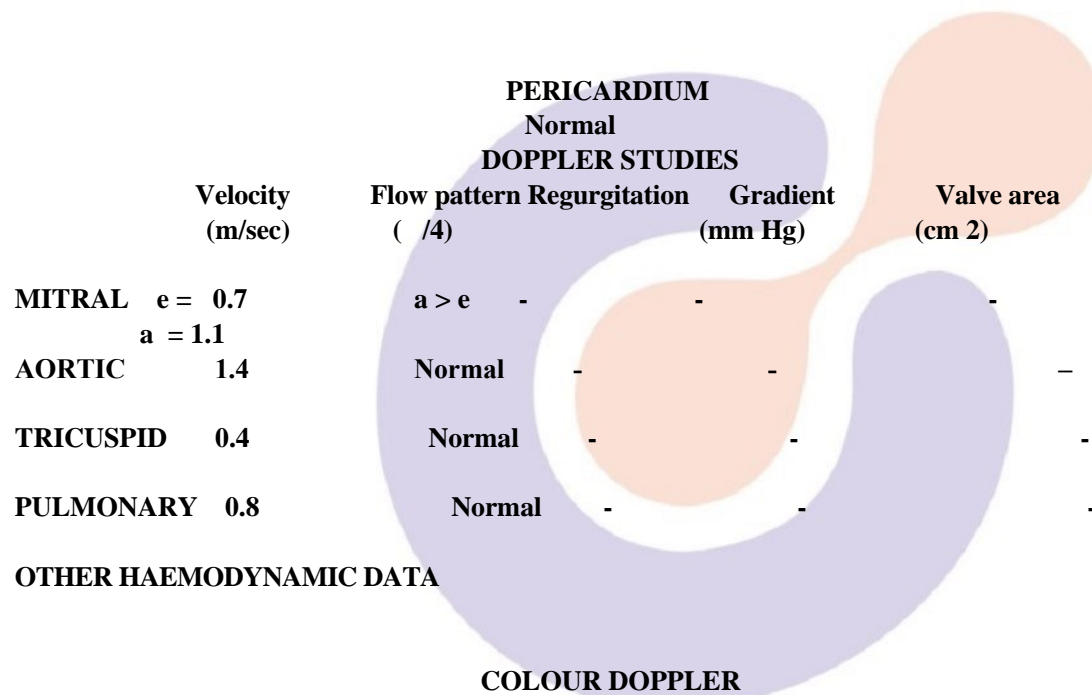
NO RWMA

Apical 4 chamber View :

No LV CLOT



Patient Name	: Mr. BECHE LAL	Visit No	: CHA250042701
Age/Gender	: 56 Y O M O D /M	Registration ON	: 10/Mar/2025 08:13AM
Lab No	: 10139996	Sample Collected ON	: 10/Mar/2025 08:13AM
Referred By	: Dr.CIVIL HOSPITAL	Sample Received ON	:
Refer Lab/Hosp	: CHARAK NA	Report Generated ON	: 10/Mar/2025 11:06AM



NO REGURGITATION OR TURBULENCE ACROSS ANY VALVE

CONCLUSIONS :

- CONCENTRIC LVH
- GOOD LV SYSTOLIC FUNCTION
- LVEF = 72 %
- NO RWMA
- a > e, DIASTOLIC DYSFUNCTION
- NO CLOT / VEGETATION
- NO PERICARDIAL EFFUSION

OPINION – CONCENTRIC LVH

DR. PANKAJ RASTOGI MD.DM



Patient Name	: Mr. BECHE LAL	Visit No	: CHA250042701
Age/Gender	: 56 Y O M O D /M	Registration ON	: 10/Mar/2025 08:13AM
Lab No	: 10139996	Sample Collected ON	: 10/Mar/2025 08:13AM
Referred By	: Dr.CIVIL HOSPITAL	Sample Received ON	:
Refer Lab/Hosp	: CHARAK NA	Report Generated ON	: 10/Mar/2025 11:06AM

*** End Of Report ***

