

Patient Name : Ms. RAM DULARI Visit No : CHA250044379  
Age/Gender : 37 Y/F Registration ON : 12/Mar/2025 09:38AM  
**Lab No : 10141674** Sample Collected ON : 12/Mar/2025 09:38AM  
Referred By : Dr.ESIC HOSPITAL LUCKNOW Sample Received ON :  
Refer Lab/Hosp : ESIC HOSPITAL LUCKNOW Report Generated ON : 12/Mar/2025 11:00AM

**2D- ECHO & COLOR DOPPLER REPORT**

1. MITRAL VALVE STUDY : MVOA - Normal (perimetry) cm2 (PHT)

**Anterior Mitral Leaflet:**

(a) Motion: Normal (b) Thickness : Normal (c) DE : 1.7 cm.  
(d) EF : 120 mm/sec (e) EPSS : 06 mm (f) Vegetation : -  
(g) Calcium : -

**Posterior mitral leaflet : Normal**

(a). Motion : Normal (b) Calcium: - (c) Vegetation : -  
Valve Score : Mobility /4 Thickness /4 SVA /4  
Calcium /4 Total /16

2. AORTIC VALVE STUDY

(a) Aortic root : 2.7cms (b) Aortic Opening : 1.6cms (c) Closure: Central  
(d) Calcium : - (e) Eccentricity Index : 1 (f) Vegetation : -

(g) Valve Structure : Tricuspid,

3. PULMONARY VALVE STUDY

(a) EF Slope : - (b) A Wave : + (c) MSN : -

(D) Thickness : (e) Others :

4. TRICUSPID VALVE : Normal

5. SEPTAL AORTIC CONTINUITY 6. AORTIC MITRAL CONTINUITY

Left Atrium : 3.5 cms Clot : - Others :  
Right Atrium : Normal Clot : - Others : -

Contd.....



Patient Name	: Ms.RAM DULARI	Visit No	: CHA250044379
Age/Gender	: 37 Y/F	Registration ON	: 12/Mar/2025 09:38AM
<b>Lab No</b>	<b>: 10141674</b>	Sample Collected ON	: 12/Mar/2025 09:38AM
Referred By	: Dr.ESIC HOSPITAL LUCKNOW	Sample Received ON	:
Refer Lab/Hosp	: ESIC HOSPITAL LUCKNOW	Report Generated ON	: 12/Mar/2025 11:00AM

**VENTRICLES**

**RIGHT VENTRICLE** : Normal

**RVD (D)**  
**RVOT**

**LEFT VENTRICLE** :

**LVIVS (D)** 0.8 cm (s) 1.3 cm

**Motion** : normal

**LVPW (D)** 0.8cm (s) 1.4 cm

**Motion** : Normal

**LVID (D)** 5.0 cm (s)3.2 cm

**Ejection Fraction** :65%

**Fractional Shortening** : 36%

**TOMOGRAPHIC VIEWS**

**Parasternal Long axis view** :

NORMAL LV RV DIMENSION  
GOOD LV CONTRACTILITY.

**Short axis view**

**Aortic valve level** :

AOV - NORMAL  
**PV - NORMAL**  
TV - NORMAL

**Mitral valve level** :

MV - NORMAL

**Papillary Muscle Level** :

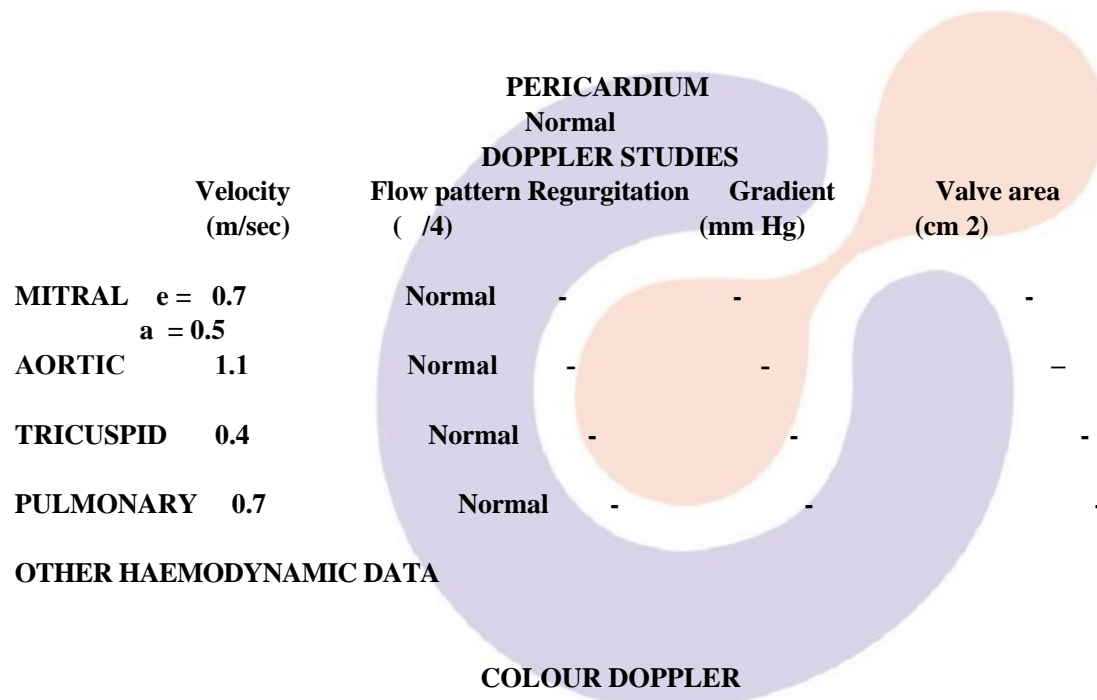
NO RWMA

**Apical 4 chamber View** :

No LV CLOT



Patient Name	: Ms.RAM DULARI	Visit No	: CHA250044379
Age/Gender	: 37 Y/F	Registration ON	: 12/Mar/2025 09:38AM
<b>Lab No</b>	<b>: 10141674</b>	Sample Collected ON	: 12/Mar/2025 09:38AM
Referred By	: Dr.ESIC HOSPITAL LUCKNOW	Sample Received ON	:
Refer Lab/Hosp	: ESIC HOSPITAL LUCKNOW	Report Generated ON	: 12/Mar/2025 11:00AM



NO REGURGITATION OR TURBULENCE ACROSS ANY VALVE

**CONCLUSIONS :**

- NORMAL LV RV DIMENSION
- GOOD LV SYSTOLIC FUNCTION
- LVEF = 65%
- NO RWMA
- ALL VALVES NORMAL
- NO CLOT / VEGETATION
- NO PERICARDIAL EFFUSION

**OPINION – NORMAL 2D-ECHO & COLOUR DOPPLER STUDY**

**DR. PANKAJ RASTOGI MD.DM**



Patient Name	: Ms.RAM DULARI	Visit No	: CHA250044379
Age/Gender	: 37 Y/F	Registration ON	: 12/Mar/2025 09:38AM
<b>Lab No</b>	<b>: 10141674</b>	Sample Collected ON	: 12/Mar/2025 09:38AM
Referred By	: Dr.ESIC HOSPITAL LUCKNOW	Sample Received ON	:
Refer Lab/Hosp	: ESIC HOSPITAL LUCKNOW	Report Generated ON	: 12/Mar/2025 11:00AM

\*\*\* End Of Report \*\*\*



CHARAK

