

Patient Name	: Ms.BATOOL BEGUM	Visit No	: CHA250045600
Age/Gender	: 65 Y/F	Registration ON	: 15/Mar/2025 09:04AM
Lab No	: 10142895	Sample Collected ON	: 15/Mar/2025 09:04AM
Referred By	: Dr.MOHD RIZWANUL HAQUE	Sample Received ON	:
Refer Lab/Hosp	: CHARAK NA	Report Generated ON	: 15/Mar/2025 09:53AM

ECG -REPORT

RATE : 86 bpm

* RHYTHM : Normal

* P wave : Normal

* PR interval : Normal

* QRS Axis : Normal

Duration : Normal

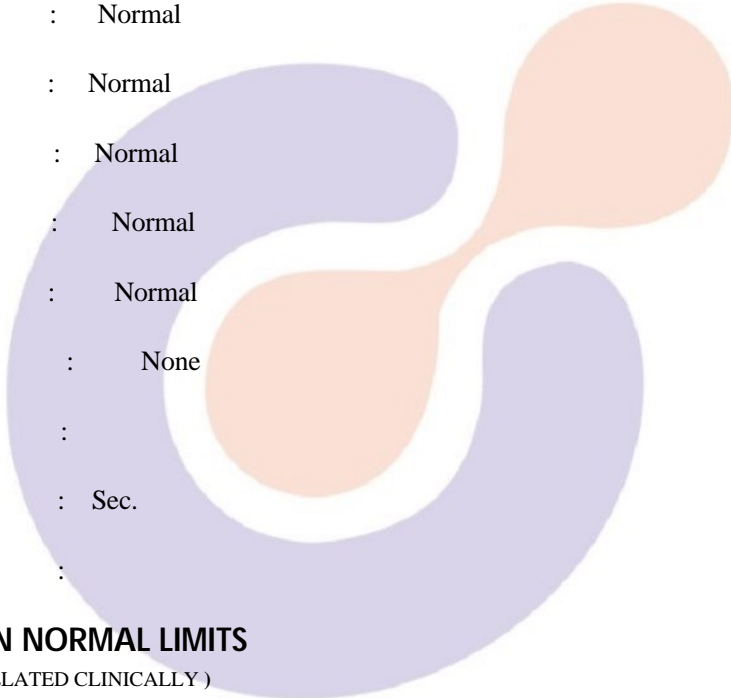
Configuration : Normal

* ST-T Changes : None

* QT interval :

* QTc interval : Sec.

* Other :



OPINION: ECG WITH IN NORMAL LIMITS
(FINDING TO BE CORRELATED CLINICALLY)

CHARAK

[DR. PANKAJ RASTOGI, MD, DM]



Patient Name	: Ms.BATOOL BEGUM	Visit No	: CHA250045600
Age/Gender	: 65 Y/F	Registration ON	: 15/Mar/2025 09:04AM
Lab No	: 10142895	Sample Collected ON	: 15/Mar/2025 09:04AM
Referred By	: Dr.MOHD RIZWANUL HAQUE	Sample Received ON	:
Refer Lab/Hosp	: CHARAK NA	Report Generated ON	: 15/Mar/2025 02:56PM

SKIAGRAM CHEST PA VIEW

- Fibro-calcific opacities are seen in right infra clavicular region.
- Bilateral hilar shadows are prominent.
- Cardiac shadow is within normal limits.
- Both CP angles are clear.
- Soft tissue and bony cage are seen normally.
- Humping of right dome of diaphragm is seen.

OPINION:

- **SEQUELAE OF KOCH'S CHEST.**

Please compare with previous skiagram.

[DR. RAJESH KUMAR SHARMA, MD]

Transcribed By: Purvi

CHARAK

*** End Of Report ***

