

Patient Name	: Mr.MOHD IRFAN	Visit No	: CHA250046234
Age/Gender	: 50 Y/M	Registration ON	: 16/Mar/2025 10:42AM
Lab No	: 10143529	Sample Collected ON	: 16/Mar/2025 10:42AM
Referred By	: Dr.MERAJ RASOOL	Sample Received ON	:
Refer Lab/Hosp	: CHARAK NA	Report Generated ON	: 16/Mar/2025 12:48PM

2D- ECHO & COLOR DOPPLER REPORT

1. MITRAL VALVE STUDY : MVOA - Normal (perimetry) cm2 (PHT)

Anterior Mitral Leaflet:

- (a) Motion: Normal (b) Thickness : Normal (c) DE : 1.8 cm.
(d) EF :85 mm/sec (e) EPSS : 06 mm (f) Vegetation : -
(g) Calcium : -

Posterior mitral leaflet : Normal

- (a). Motion : Normal (b) Calcium: - (c) Vegetation : -
Valve Score : Mobility /4 Thickness /4 SVA /4
Calcium /4 Total /16

2. AORTIC VALVE STUDY

- (a) Aortic root :2.9cms (b) Aortic Opening :1.6cms (c) Closure: Central
(d) Calcium : - (e) Eccentricity Index : 1 (f) Vegetation : -

(g) Valve Structure : Tricuspid,

3. PULMONARY VALVE STUDY

- (a) EF Slope : - (b) A Wave : + (c) MSN : -

- (D) Thickness : (e) Others :

4. TRICUSPID VALVE : Normal

5. SEPTAL AORTIC CONTINUITY 6. AORTIC MITRAL CONTINUITY

- Left Atrium : 4.2 cms Clot : - Others :
Right Atrium : Normal Clot : - Others : -

Contd.....



Patient Name	: Mr.MOHD IRFAN	Visit No	: CHA250046234
Age/Gender	: 50 Y/M	Registration ON	: 16/Mar/2025 10:42AM
Lab No	: 10143529	Sample Collected ON	: 16/Mar/2025 10:42AM
Referred By	: Dr.MERAJ RASOOL	Sample Received ON	:
Refer Lab/Hosp	: CHARAK NA	Report Generated ON	: 16/Mar/2025 12:48PM

VENTRICLES

RIGHT VENTRICLE : Normal

RVD (D)
RVOT

LEFT VENTRICLE :

LVIVS (D) 1.2 cm (s) 1.5 cm

Motion : normal

LVPW (D) 1.2cm (s) 1.5 cm

Motion : Normal

LVID (D) 4.3 cm (s) 3.2 cm

Ejection Fraction :48%

Fractional Shortening :24 %

TOMOGRAPHIC VIEWS

Parasternal Long axis view :

CONCENTRIC LVH
MILDLY DEPRESSED LV CONTRACTILITY.

Short axis view

Aortic valve level :

AOV - NORMAL
PV - NORMAL
TV - NORMAL

Mitral valve level :

MV - NORMAL

Papillary Muscle Level :

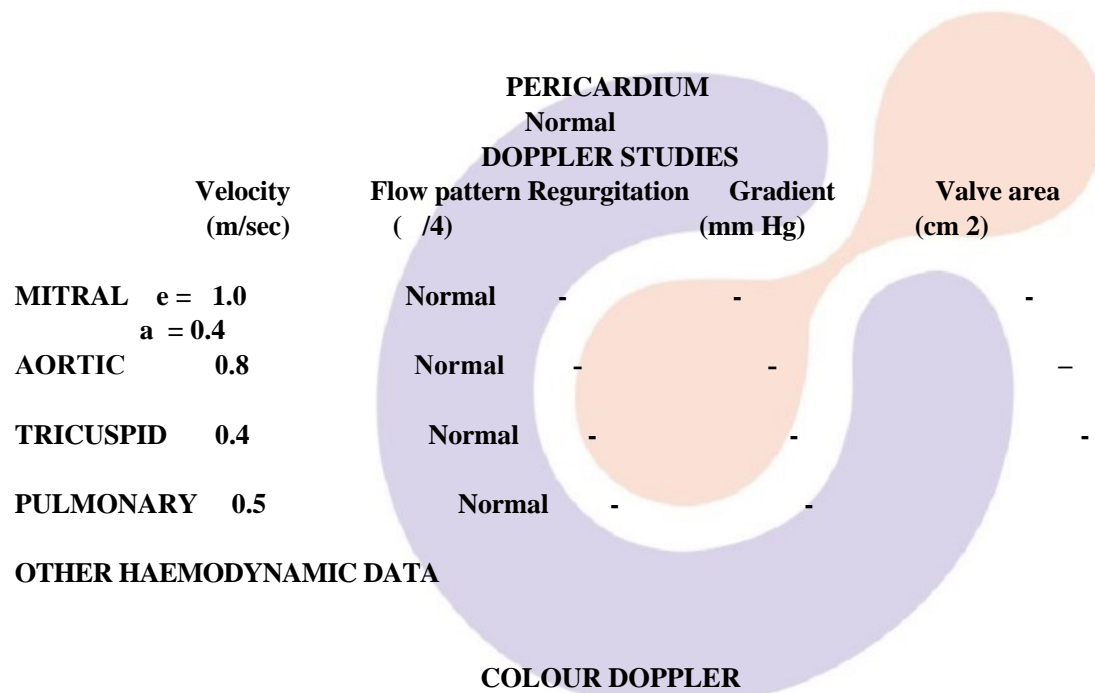
ANTERIOR IVS &APEX HYPOKINETIC

Apical 4 chamber View :

No LV CLOT



Patient Name	: Mr.MOHD IRFAN	Visit No	: CHA250046234
Age/Gender	: 50 Y/M	Registration ON	: 16/Mar/2025 10:42AM
Lab No	: 10143529	Sample Collected ON	: 16/Mar/2025 10:42AM
Referred By	: Dr.MERAJ RASOOL	Sample Received ON	:
Refer Lab/Hosp	: CHARAK NA	Report Generated ON	: 16/Mar/2025 12:48PM



NO REGURGITATION OR TURBULENCE ACROSS ANY VALVE

CONCLUSIONS :

- CONCENTRIC LVH
- MILDLY DEPRESSED LV SYSTOLIC FUNCTION
- LVEF = 48 %
- NO RWMA
- ANTERIOR IVS & APEX HYPOKINETIC
- NO CLOT / VEGETATION
- NO PERICARDIAL EFFUSION
- BILATERAL PLEURAL EFFUSION

**OPINION – LAD TERRITORY HYPOKINETIC
CONCENTRIC LVH**

DR. PANKAJ RASTOGI, MD,DM



Patient Name	: Mr.MOHD IRFAN	Visit No	: CHA250046234
Age/Gender	: 50 Y/M	Registration ON	: 16/Mar/2025 10:42AM
Lab No	: 10143529	Sample Collected ON	: 16/Mar/2025 10:42AM
Referred By	: Dr.MERAJ RASOOL	Sample Received ON	:
Refer Lab/Hosp	: CHARAK NA	Report Generated ON	: 16/Mar/2025 12:48PM

*** End Of Report ***

