

Patient Name	: Mr.MOHD AFSAR	Visit No	: CHA250046273
Age/Gender	: 25 Y/M	Registration ON	: 16/Mar/2025 11:27AM
<b>Lab No</b>	<b>: 10143568</b>	Sample Collected ON	: 16/Mar/2025 11:27AM
Referred By	: Dr.M SIDDIQUE	Sample Received ON	:
Refer Lab/Hosp	: CHARAK NA	Report Generated ON	: 16/Mar/2025 01:02PM

**2D- ECHO & COLOR DOPPLER REPORT**

1. MITRAL VALVE STUDY : MVOA - Normal (perimetry) cm2 (PHT)

**Anterior Mitral Leaflet:**

(a) Motion: Normal (b) Thickness : Normal (c) DE : 1.9 cm.  
(d) EF : 185 mm/sec (e) EPSS : 06 mm (f) Vegetation : -  
(g) Calcium : -

**Posterior mitral leaflet : Normal**

(a). Motion : Normal (b) Calcium: - (c) Vegetation : -  
Valve Score : Mobility /4 Thickness /4 SVA /4  
Calcium /4 Total /16

2. AORTIC VALVE STUDY

(a) Aortic root : 3.1cms (b) Aortic Opening : 1.8cms (c) Closure: Central  
(d) Calcium : - (e) Eccentricity Index : 1 (f) Vegetation : -

(g) Valve Structure : Tricuspid,

3. PULMONARY VALVE STUDY Normal

(a) EF Slope : - (b) A Wave : + (c) MSN : -

(D) Thickness : (e) Others :

4. TRICUSPID VALVE : Normal

5. SEPTAL AORTIC CONTINUITY 6. AORTIC MITRAL CONTINUITY

Left Atrium : 2.8 cms Clot : - Others :  
Right Atrium : Normal Clot : - Others : -

Contd.....



Patient Name	: Mr.MOHD AFSAR	Visit No	: CHA250046273
Age/Gender	: 25 Y/M	Registration ON	: 16/Mar/2025 11:27AM
<b>Lab No</b>	<b>: 10143568</b>	Sample Collected ON	: 16/Mar/2025 11:27AM
Referred By	: Dr.M SIDDIQUE	Sample Received ON	:
Refer Lab/Hosp	: CHARAK NA	Report Generated ON	: 16/Mar/2025 01:02PM

VENTRICLES

**RIGHT VENTRICLE** : Normal

**RVD (D)**  
**RVOT**

**LEFT VENTRICLE** :

**LVIVS (D)** 0.8 cm (s) 1.1 cm

**Motion** : normal

**LVPW (D)** 0.8cm (s) 1.6cm

**Motion** : Normal

**LVID (D)** 4.5 cm (s) 3.0 cm

**Ejection Fraction** :63%

**Fractional Shortening** : 34 %

TOMOGRAPHIC VIEWS

**Parasternal Long axis view** :

NORMAL LV RV DIMENSION  
GOOD LV CONTRACTILITY.

**Short axis view**

**Aortic valve level** :

AOV - NORMAL  
**PV - NORMAL**  
TV - NORMAL

**Mitral valve level** :

MV - NORMAL

**Papillary Muscle Level** :

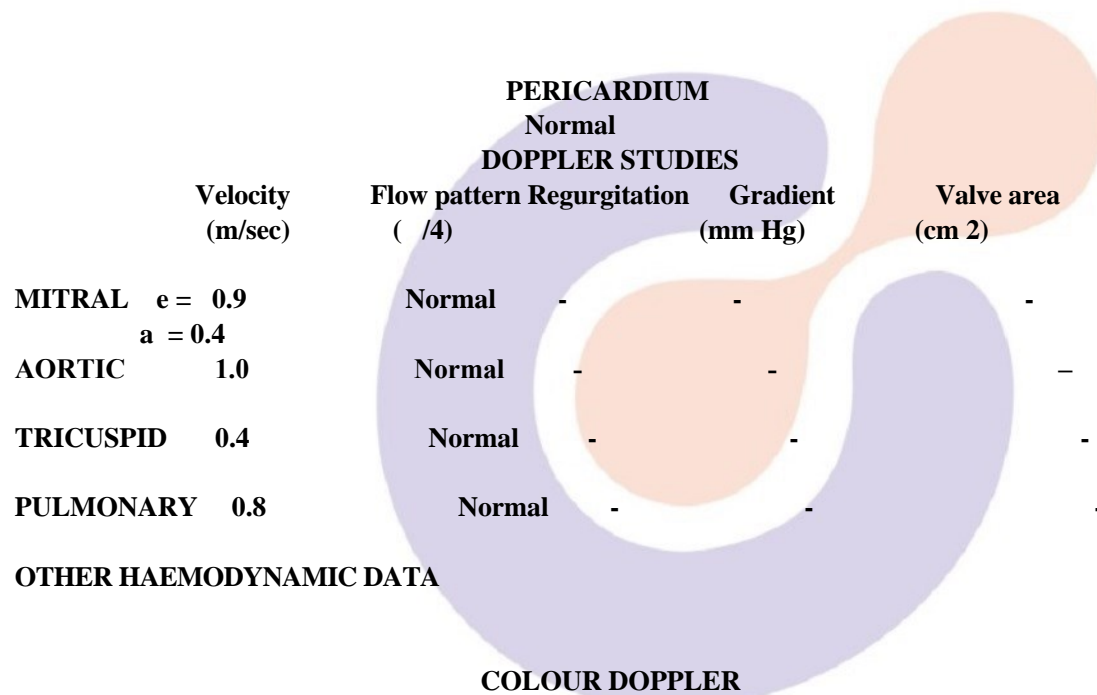
NO RWMA

**Apical 4 chamber View** :

No LV CLOT



Patient Name	: Mr. MOHD AFSAR	Visit No	: CHA250046273
Age/Gender	: 25 Y/M	Registration ON	: 16/Mar/2025 11:27AM
<b>Lab No</b>	<b>: 10143568</b>	Sample Collected ON	: 16/Mar/2025 11:27AM
Referred By	: Dr. M SIDDIQUE	Sample Received ON	:
Refer Lab/Hosp	: CHARAK NA	Report Generated ON	: 16/Mar/2025 01:02PM



NO REGURGITATION OR TURBULENCE ACROSS ANY VALVE

**CONCLUSIONS :**

- NORMAL LV RV DIMENSION
- GOOD LV SYSTOLIC FUNCTION
- LVEF = 63 %
- NO RWMA
- ALL VALVES NORMAL
- NO CLOT / VEGETATION
- NO PERICARDIAL EFFUSION

**OPINION – NORMAL 2D-ECHO & COLOUR DOPPLER STUDY**

**DR. PANKAJ RASTOGI MD.DM**



Patient Name	: Mr.MOHD AFSAR	Visit No	: CHA250046273
Age/Gender	: 25 Y/M	Registration ON	: 16/Mar/2025 11:27AM
<b>Lab No</b>	<b>: 10143568</b>	Sample Collected ON	: 16/Mar/2025 11:27AM
Referred By	: Dr.M SIDDIQUE	Sample Received ON	:
Refer Lab/Hosp	: CHARAK NA	Report Generated ON	: 16/Mar/2025 01:02PM

\*\*\* End Of Report \*\*\*

