

Patient Name	: Ms.PRIYANKA	Visit No	: CHA250046989
Age/Gender	: 29 Y/F	Registration ON	: 17/Mar/2025 12:11PM
<b>Lab No</b>	<b>: 10144284</b>	Sample Collected ON	: 17/Mar/2025 12:11PM
Referred By	: Dr.BIRLA FERTILITY IVF	Sample Received ON	:
Refer Lab/Hosp	: CHARAK NA	Report Generated ON	: 17/Mar/2025 03:56PM

**ECG -REPORT**

RATE : 94 bpm

\* RHYTHM : Normal

\* P wave : Normal

\* PR interval : Normal

\* QRS Axis : Normal

Duration : Normal

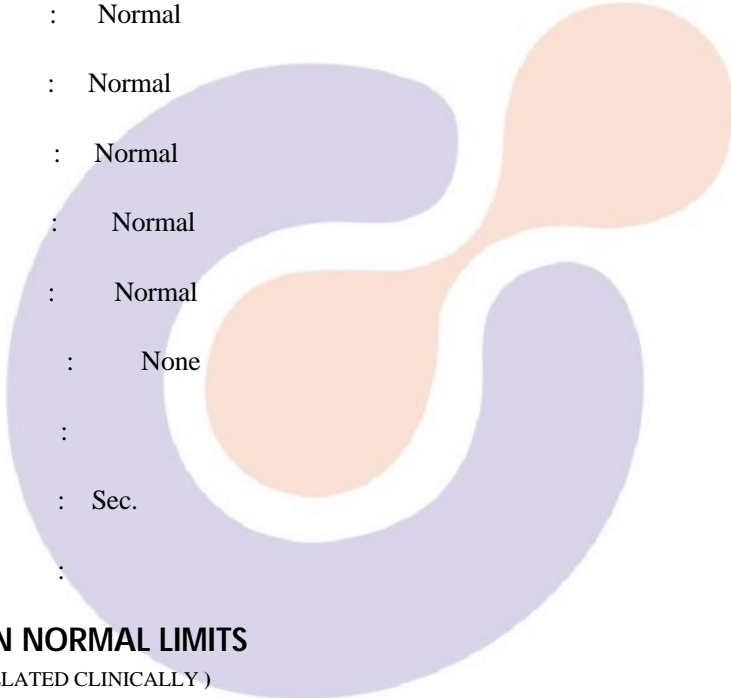
Configuration : Normal

\* ST-T Changes : None

\* QT interval :

\* QTc interval : Sec.

\* Other :



**OPINION: ECG WITH IN NORMAL LIMITS**  
(FINDING TO BE CORRELATED CLINICALLY)

[DR. RAJIV RASTOGI, MD, DM]

**CHARAK**



Patient Name	: Ms.PRIYANKA	Visit No	: CHA250046989
Age/Gender	: 29 Y/F	Registration ON	: 17/Mar/2025 12:11PM
<b>Lab No</b>	<b>: 10144284</b>	Sample Collected ON	: 17/Mar/2025 12:11PM
Referred By	: Dr.BIRLA FERTILITY IVF	Sample Received ON	:
Refer Lab/Hosp	: CHARAK NA	Report Generated ON	: 17/Mar/2025 01:25PM

**SKIAGRAM CHEST PA VIEW**

- Both lung fields are clear.
- Bilateral hilar shadows are normal.
- Cardiac shadow is within normal limits.
- Both CP angles are clear.
- Soft tissue and bony cage are seen normally.
- Both domes of diaphragm are sharply defined.

**IMPRESSION:**

- NO ACTIVE LUNG PARENCHYMAL LESION IS DISCERNIBLE.

Clinical correlation is necessary.

[DR. RAJESH KUMAR SHARMA, MD]

transcribed by: anup

**CHARAK**

\*\*\* End Of Report \*\*\*

